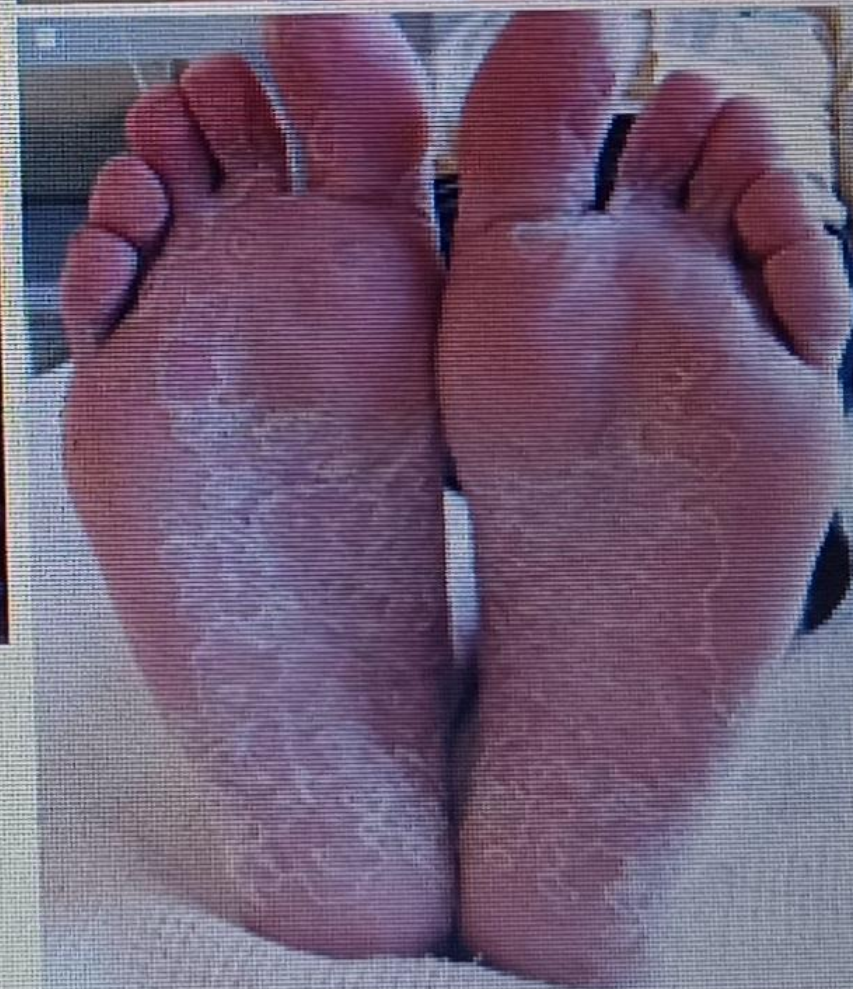
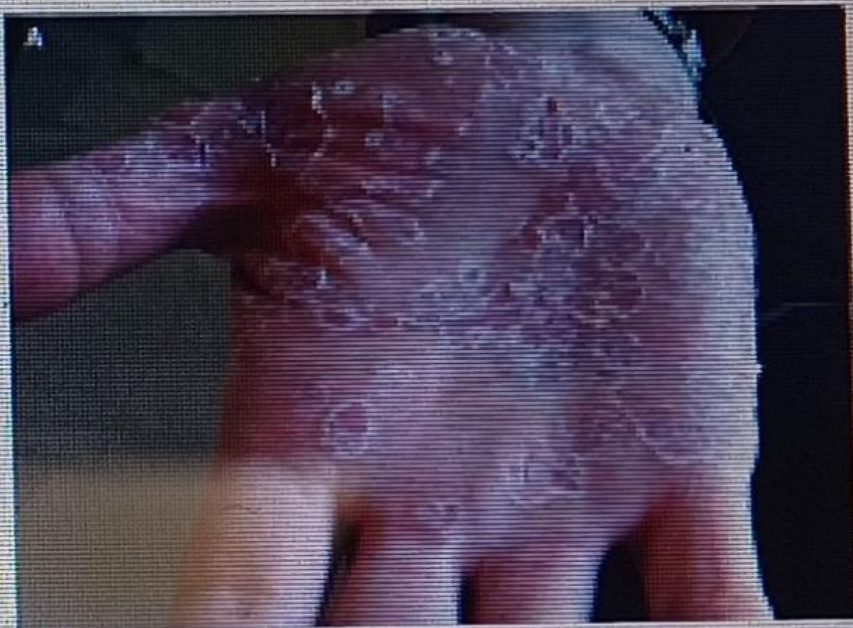
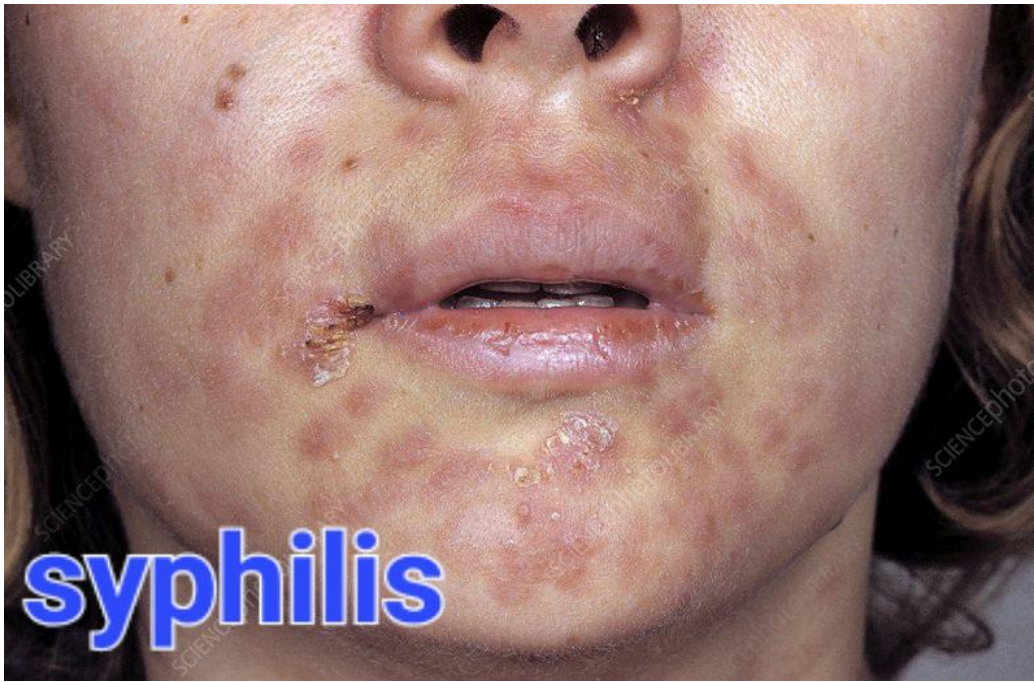
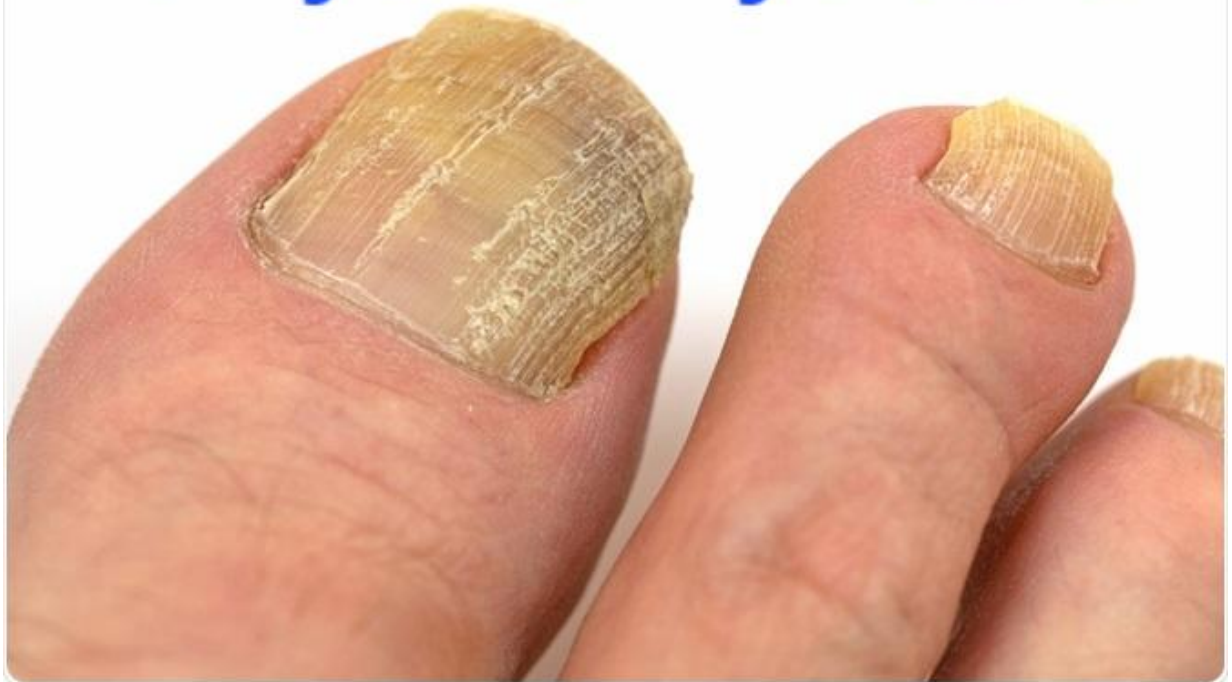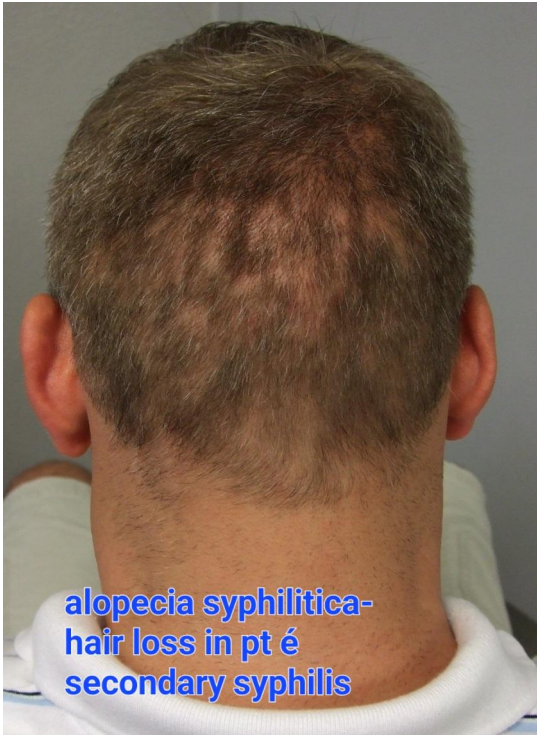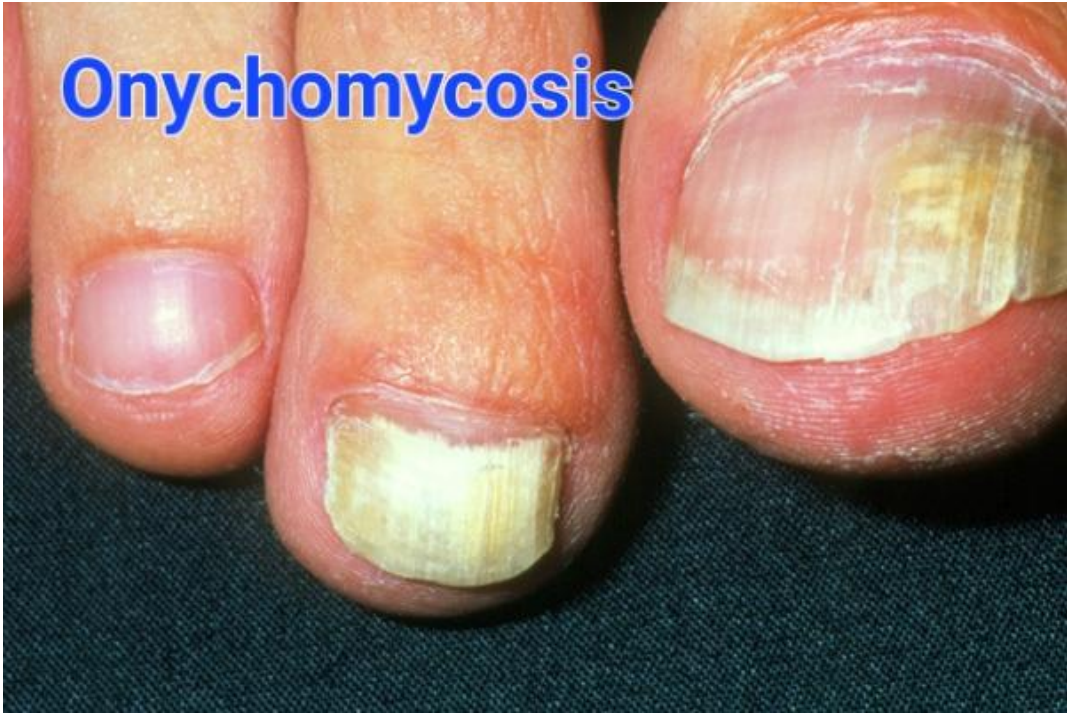syphilis



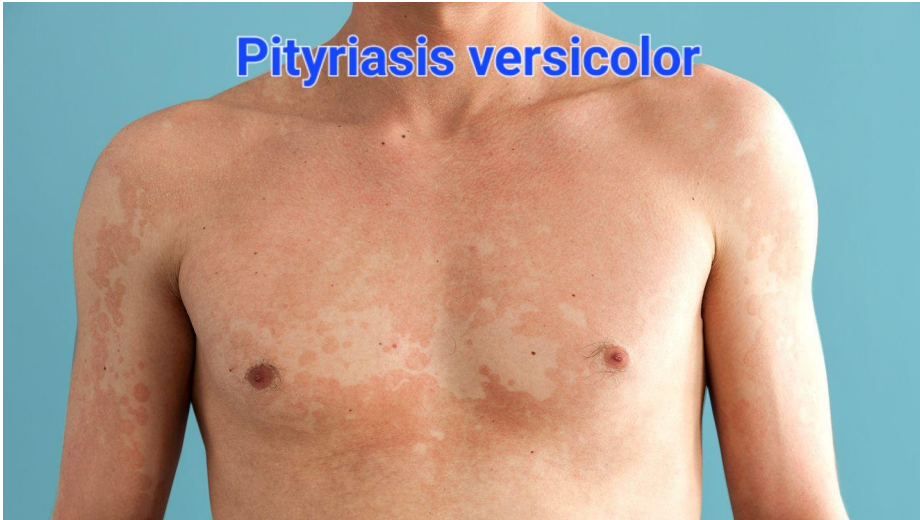

Onychomycosis

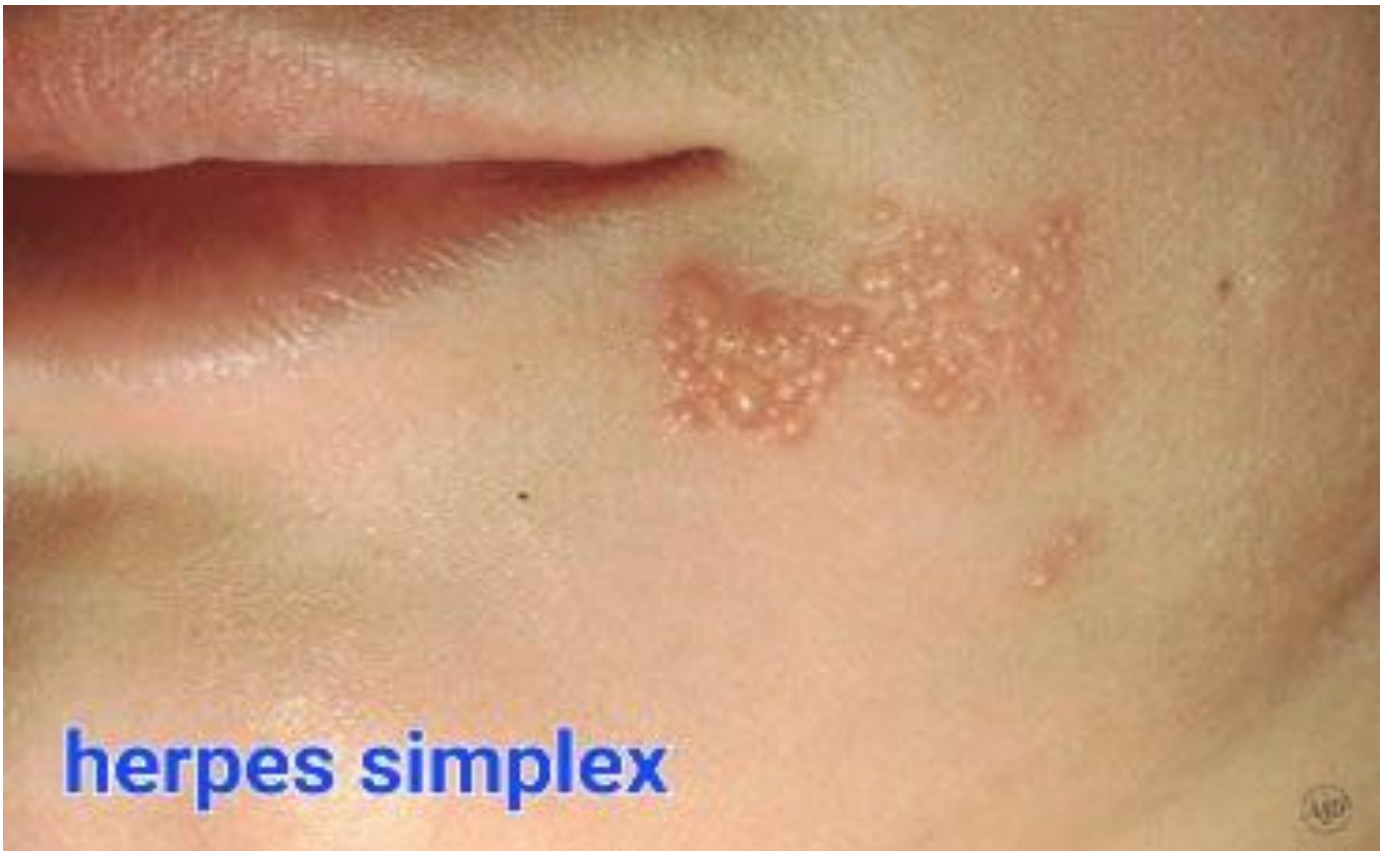



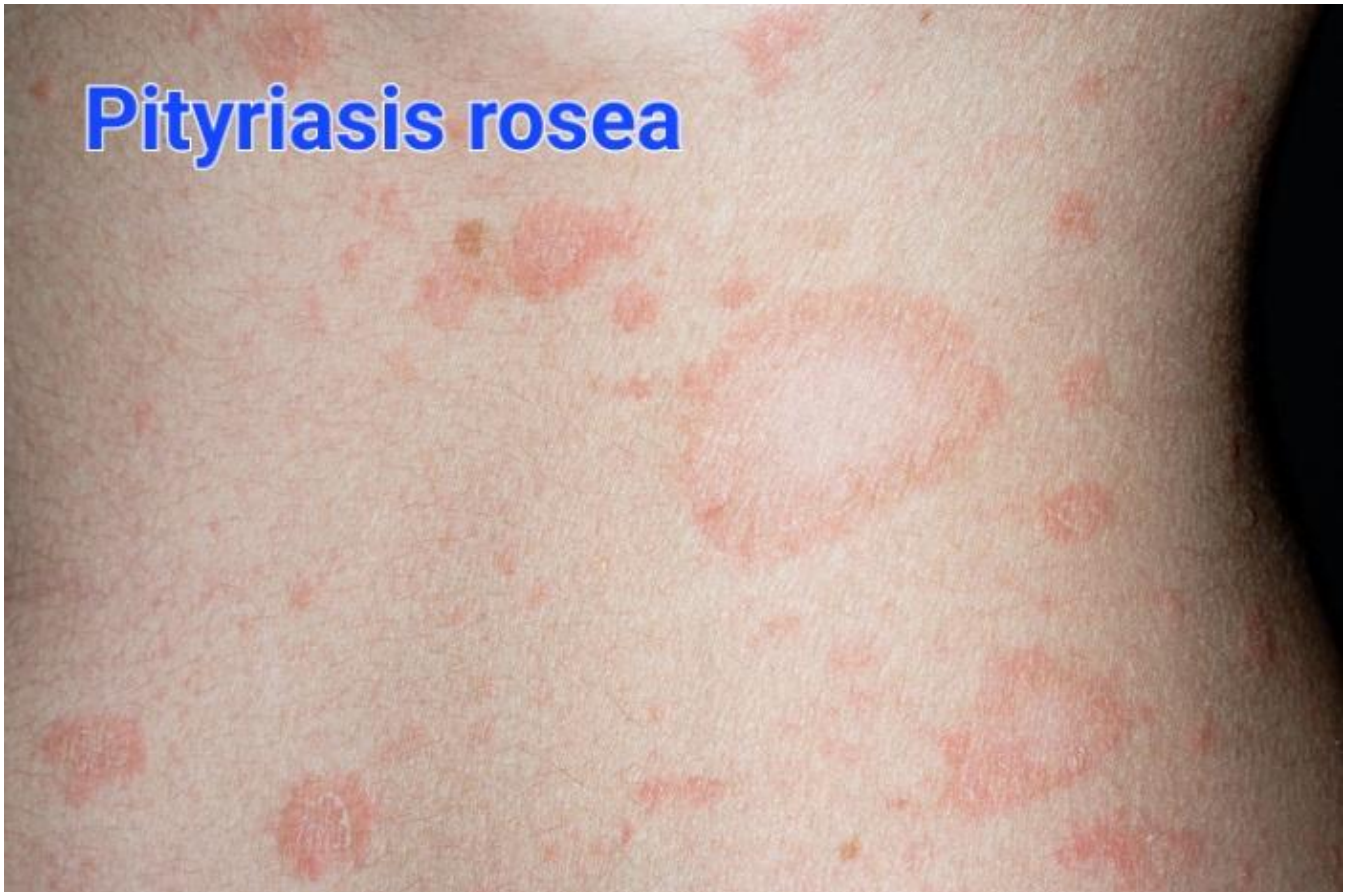Pityriasis versicolor



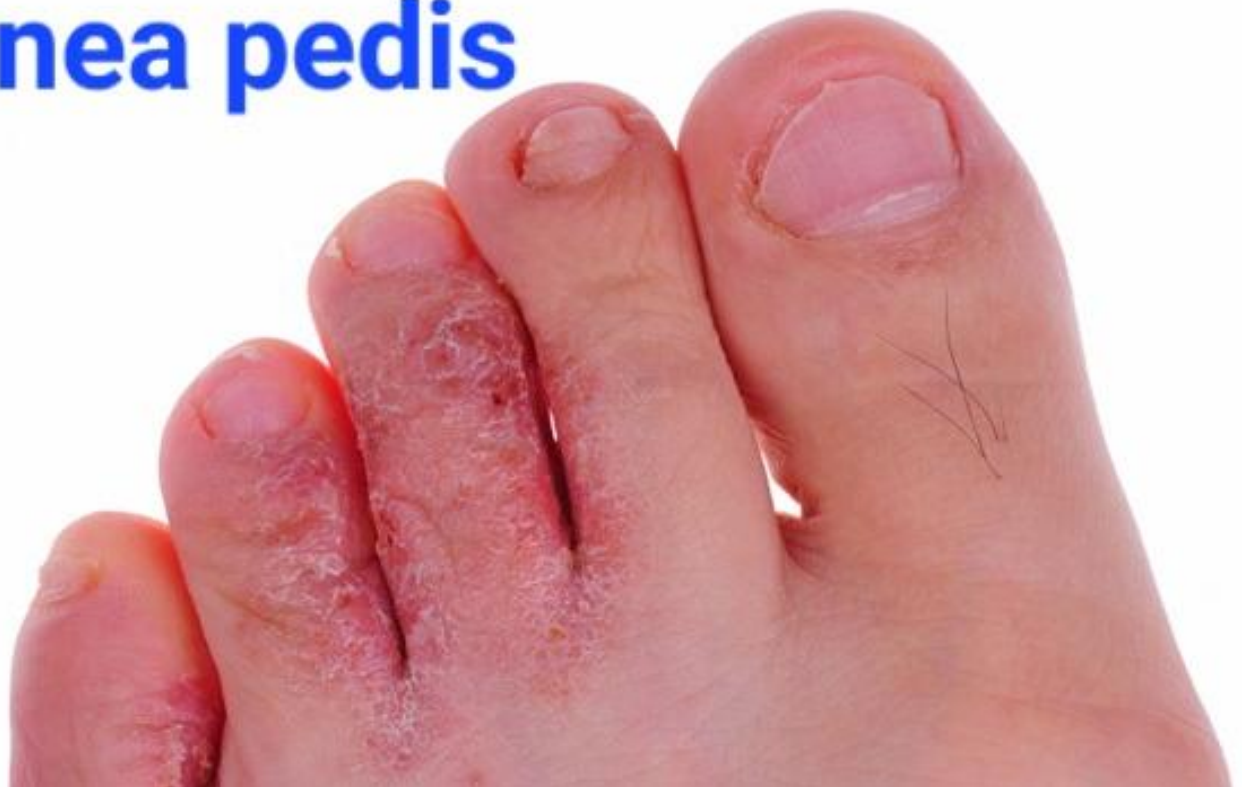herpes simplex

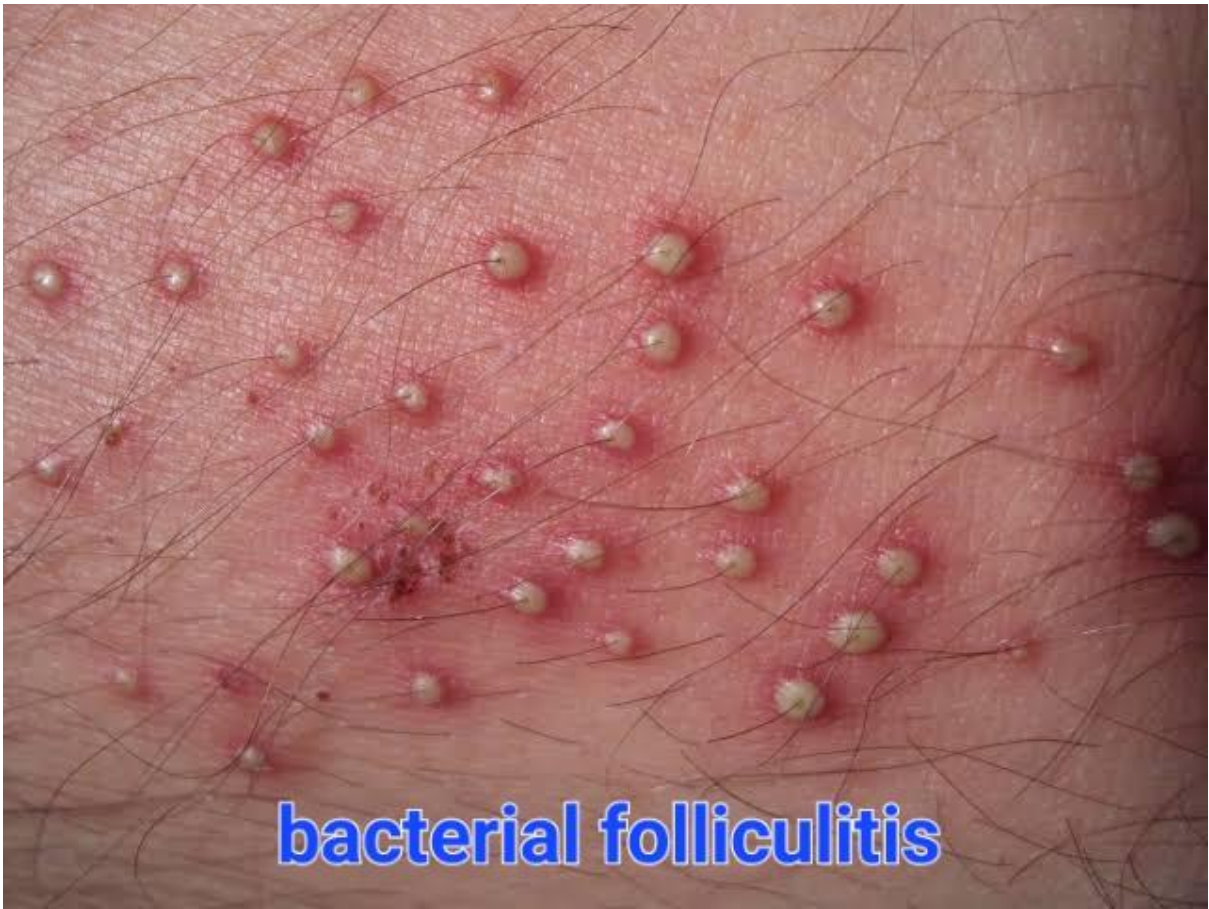
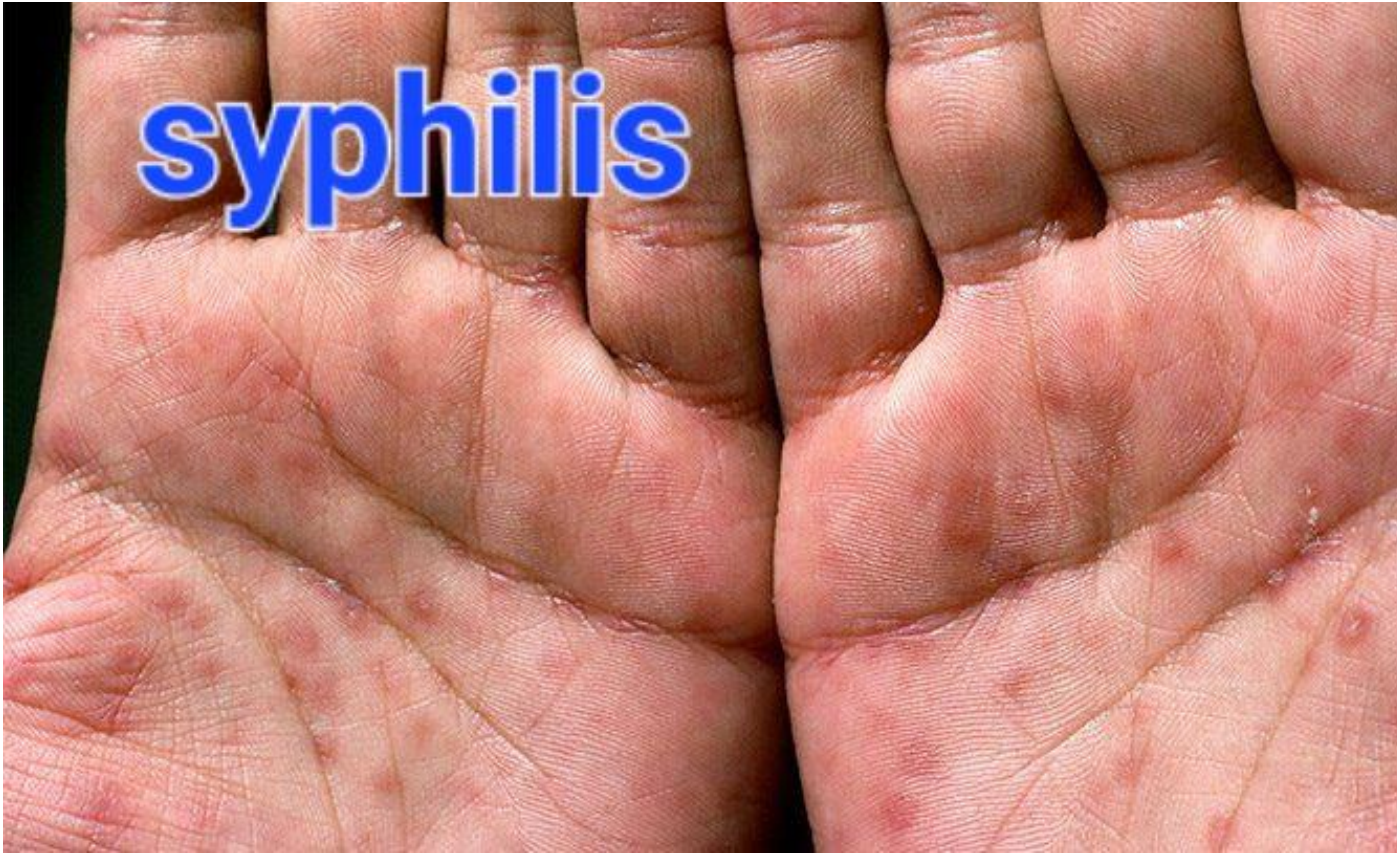
Pityriasis rosea

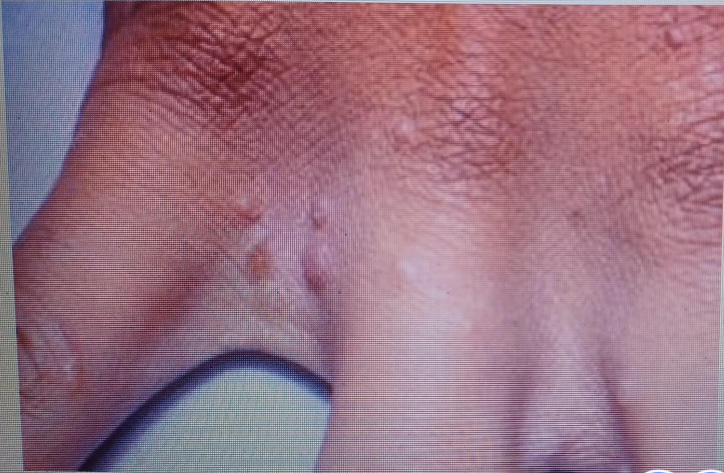

tinea pedis

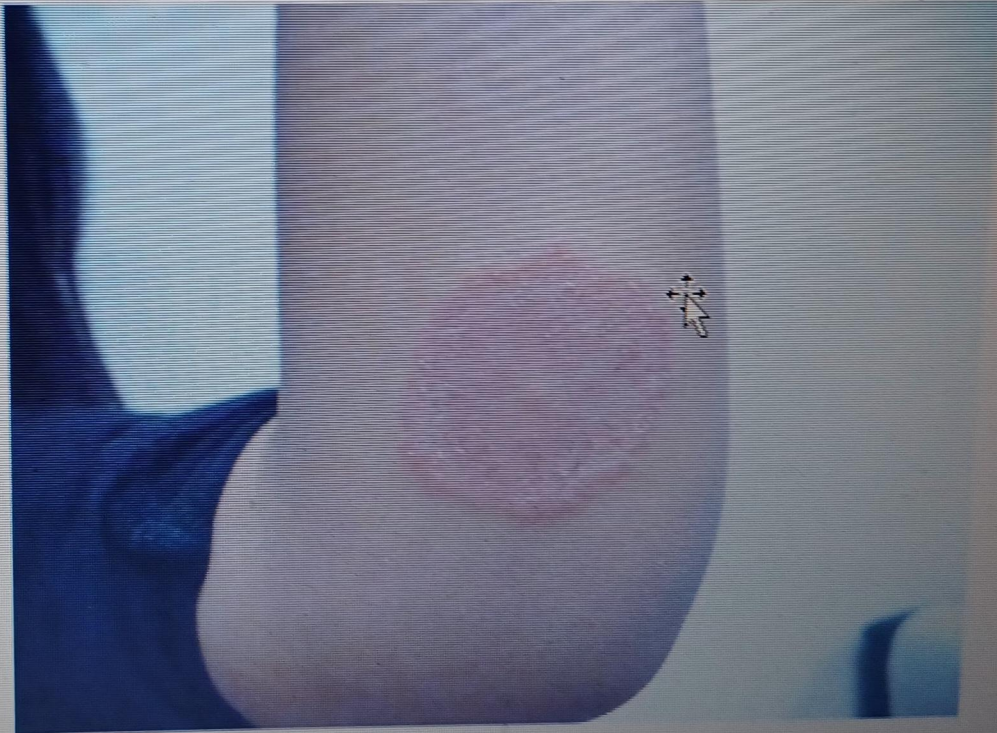



tests, prescribe the treatment

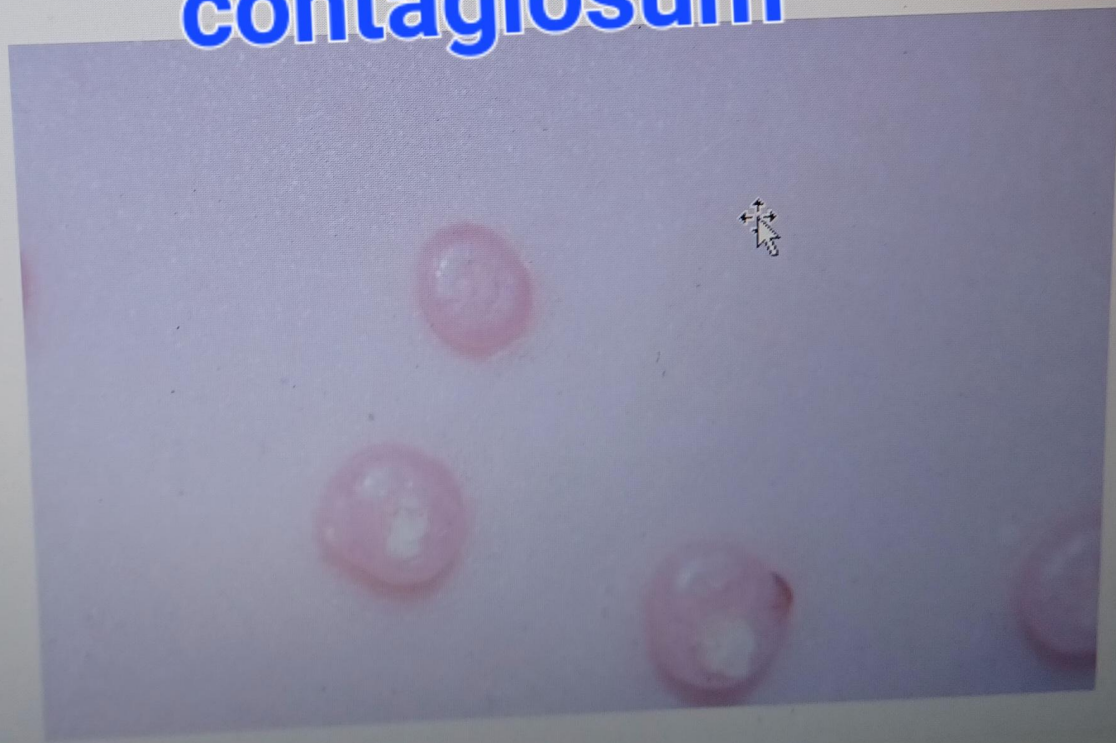

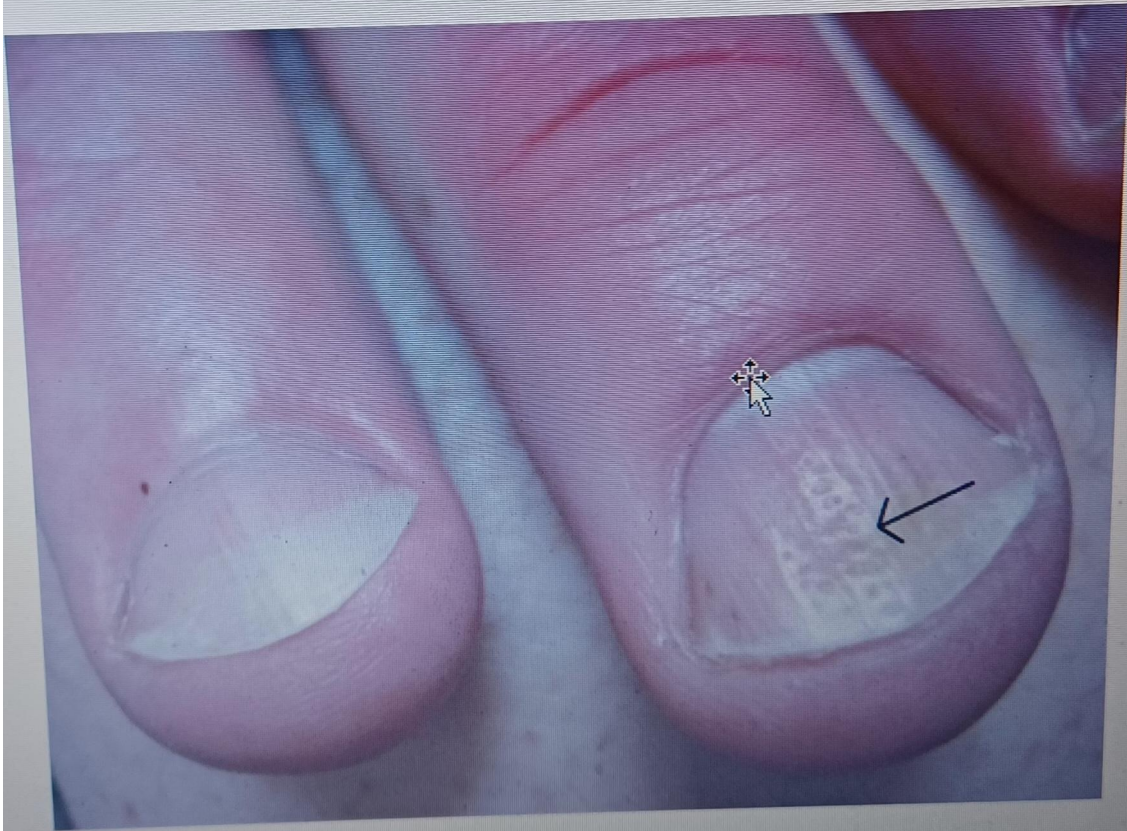scabies



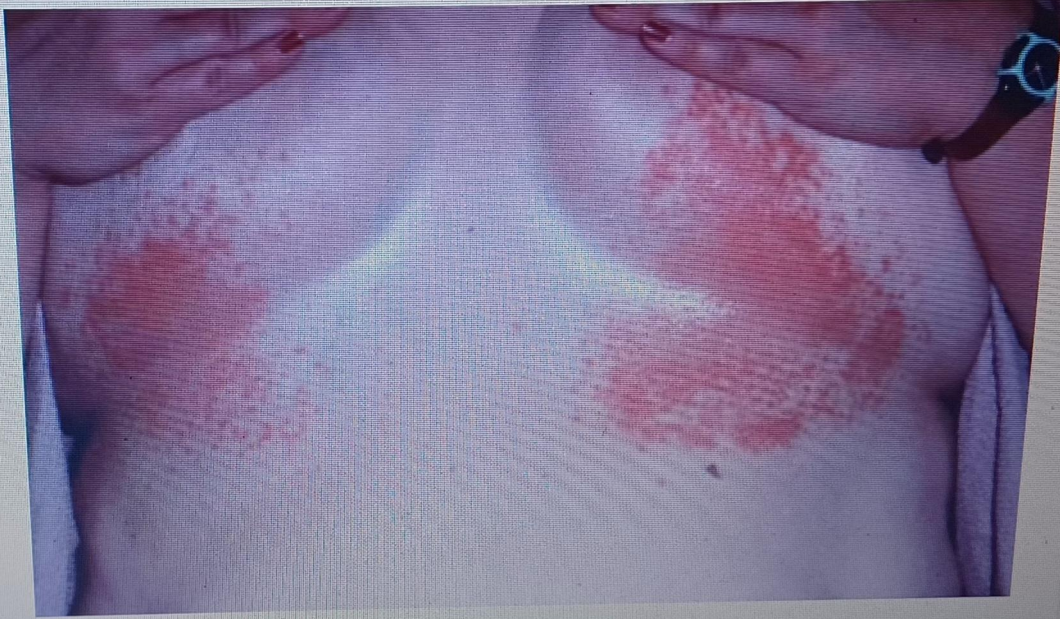tinea corporis

Molluscum contagiosum

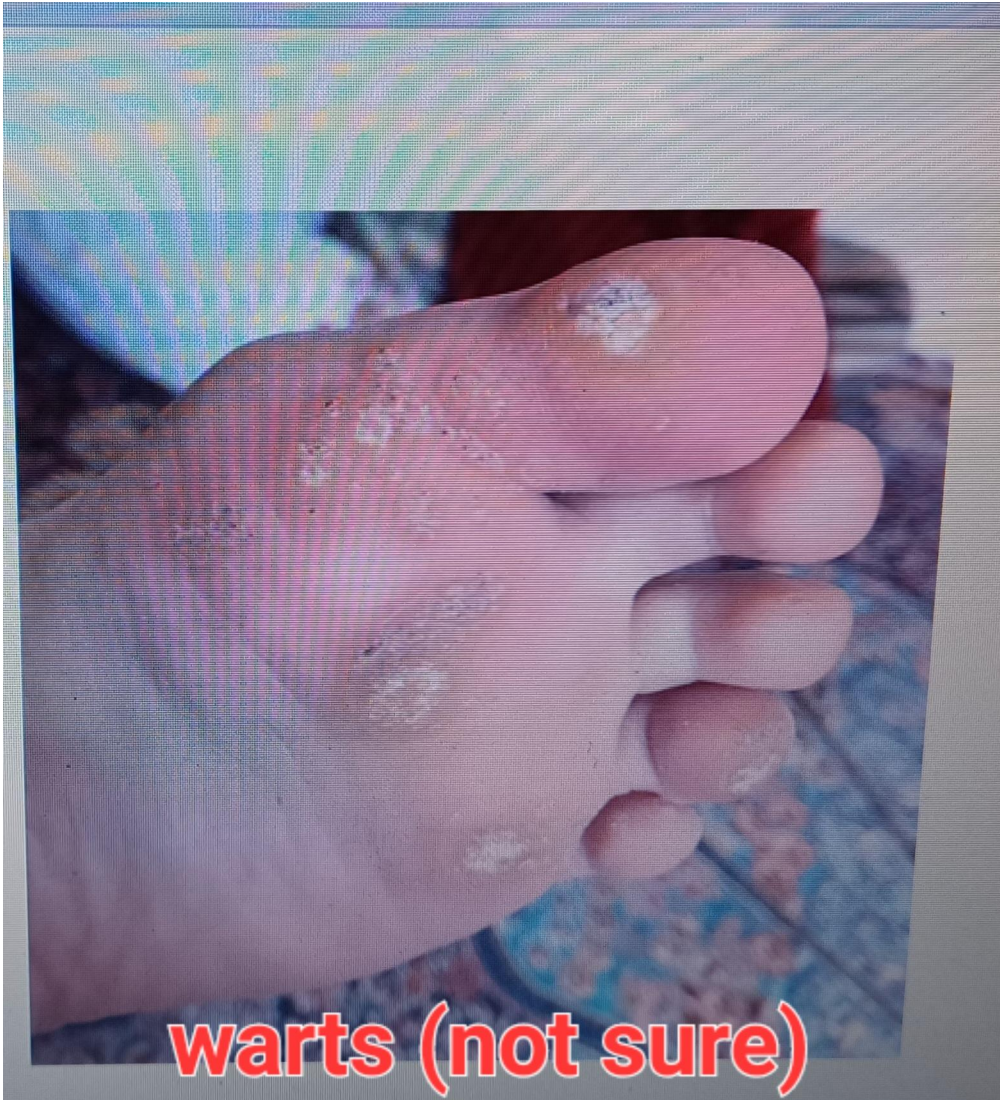




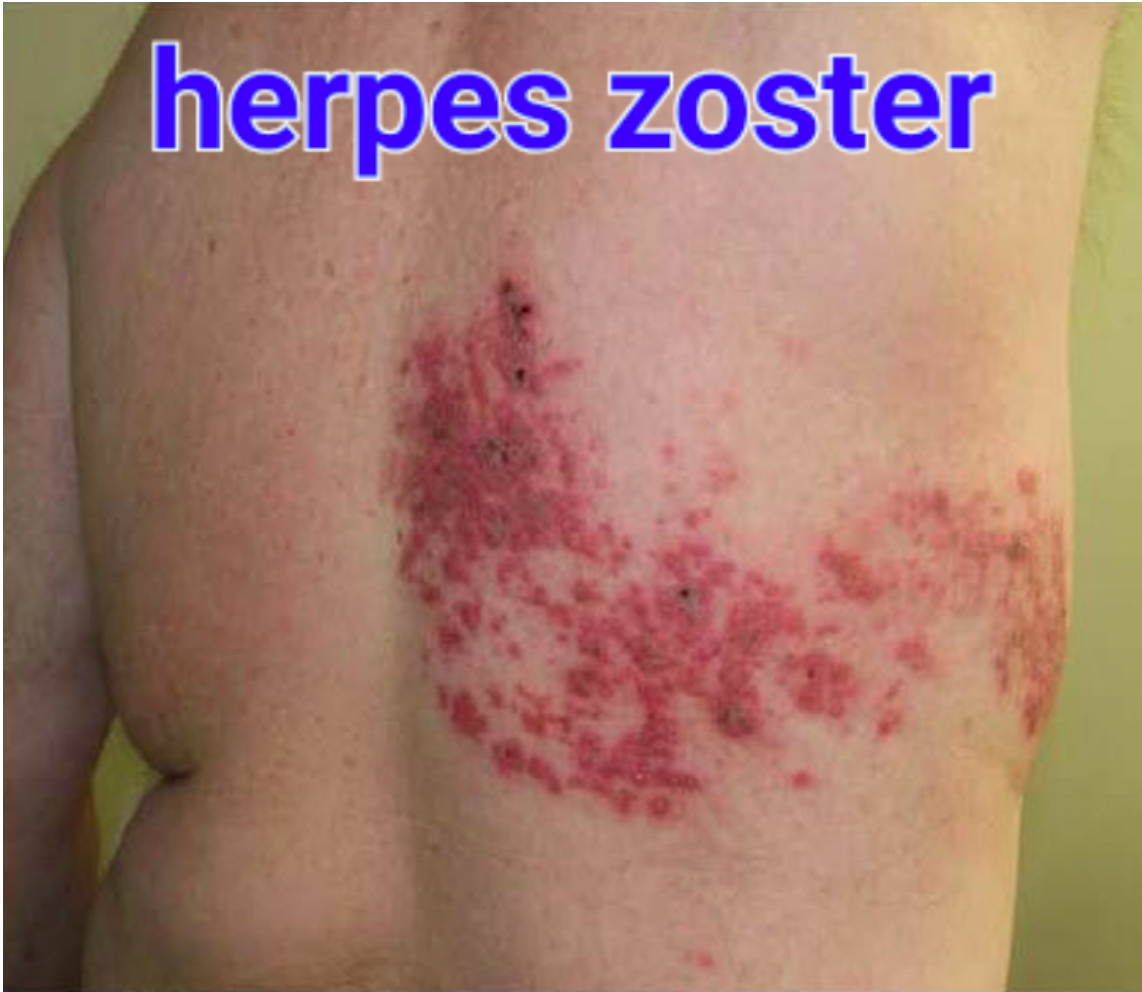nail psoriasis



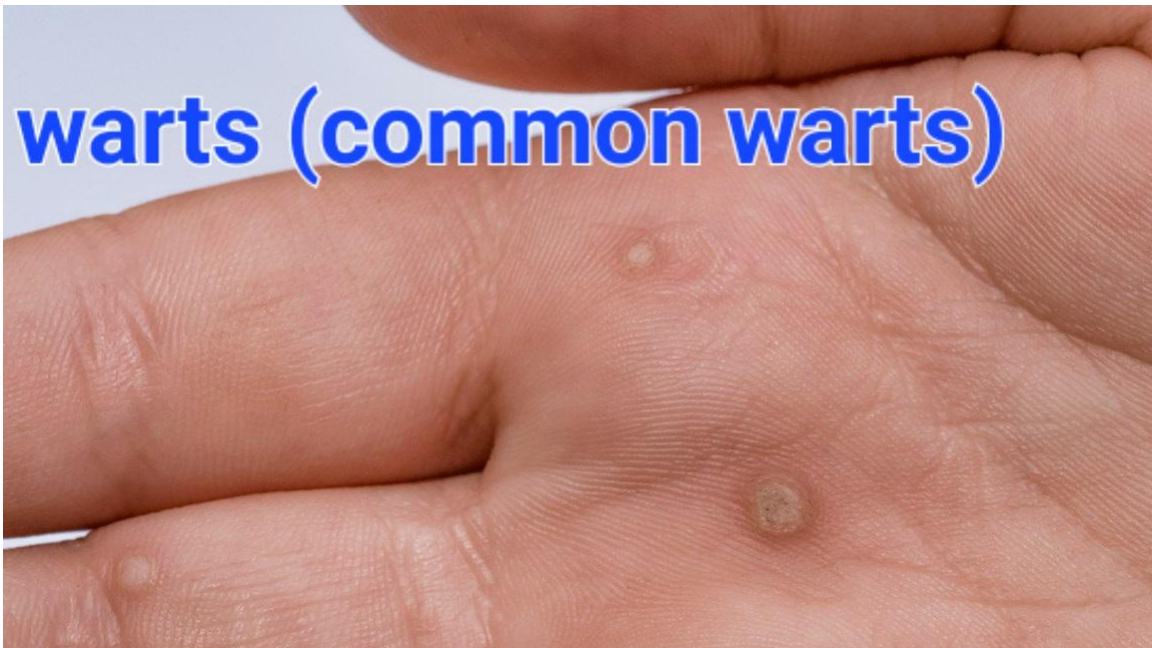intertigo

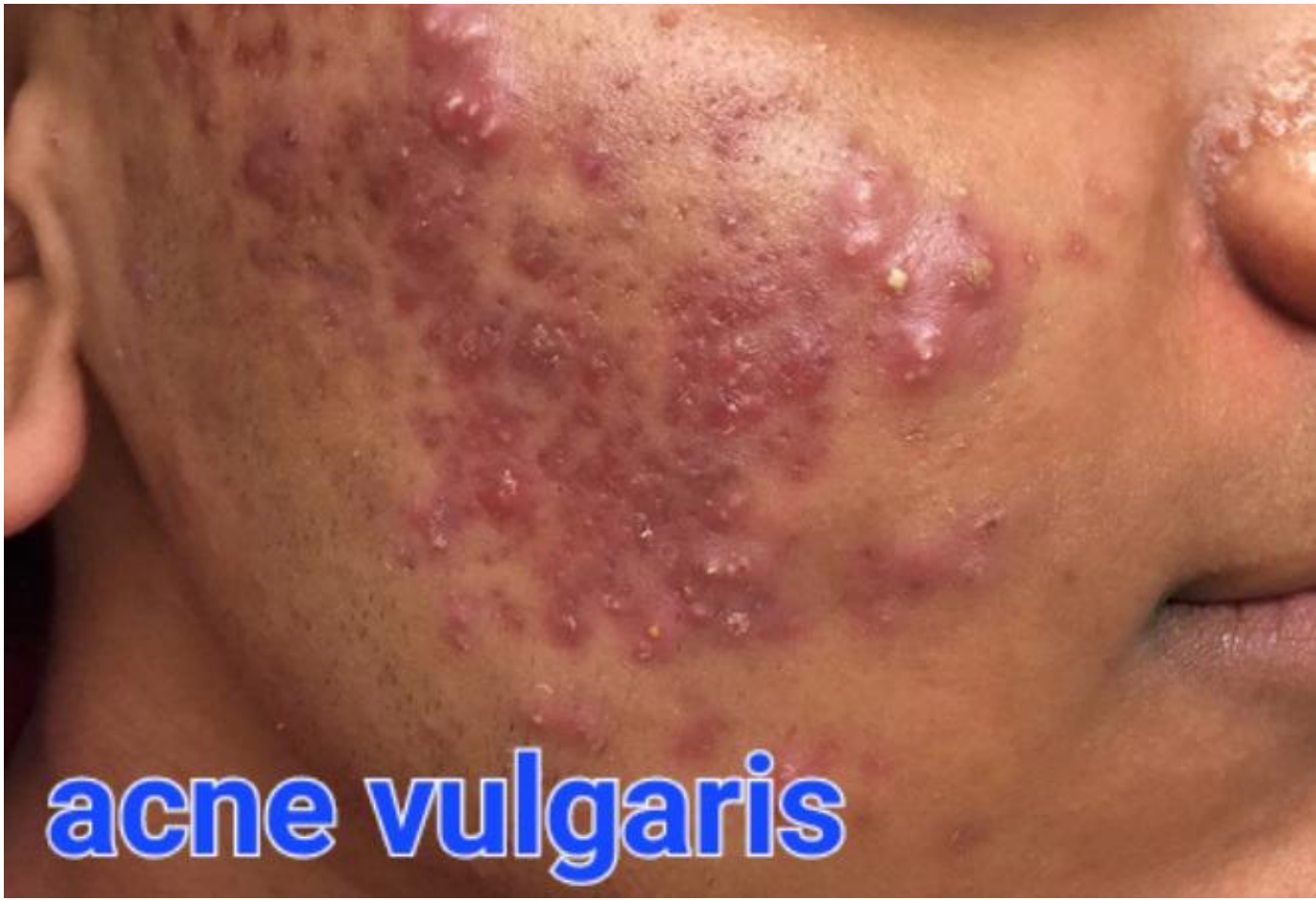

herpes zoster

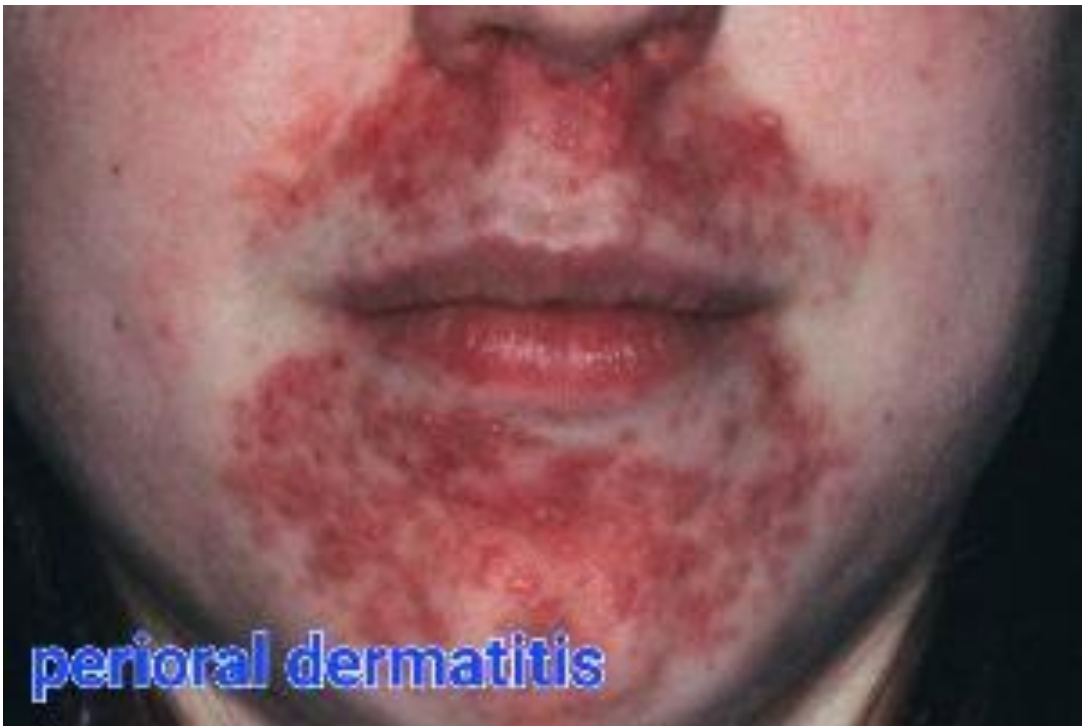
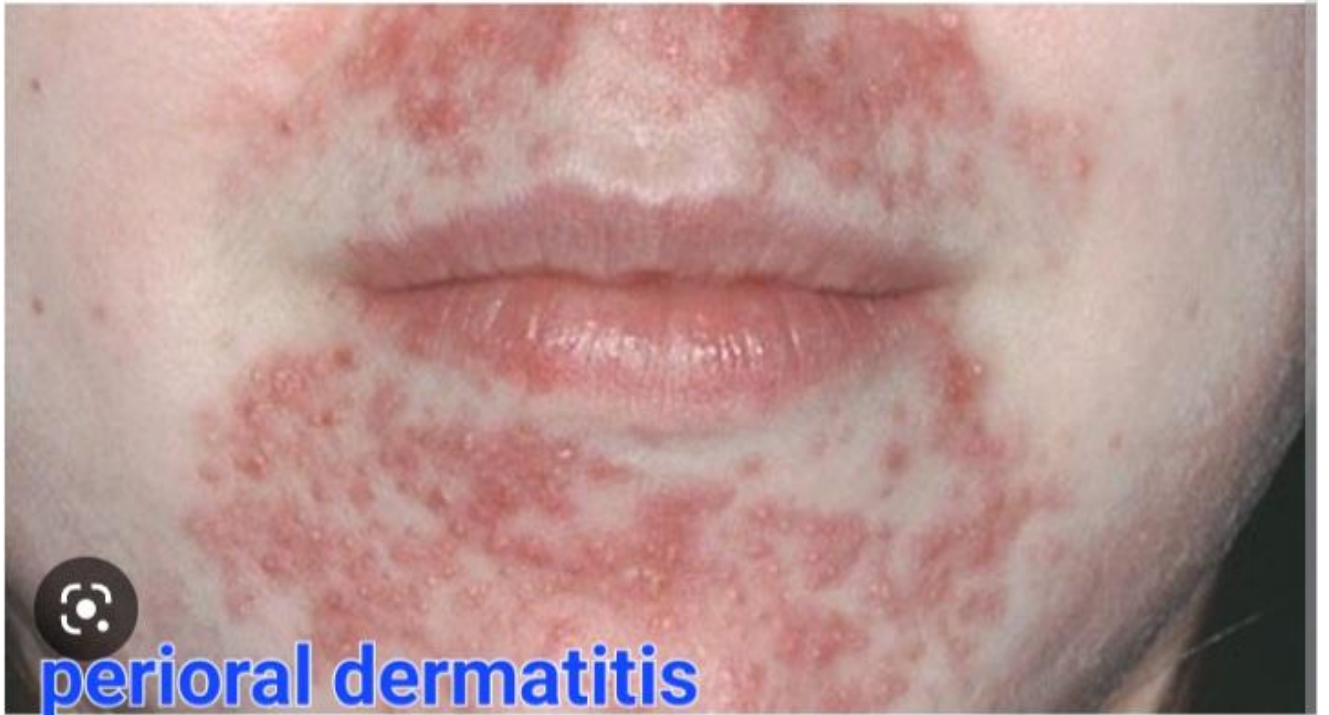
warts (common warts)

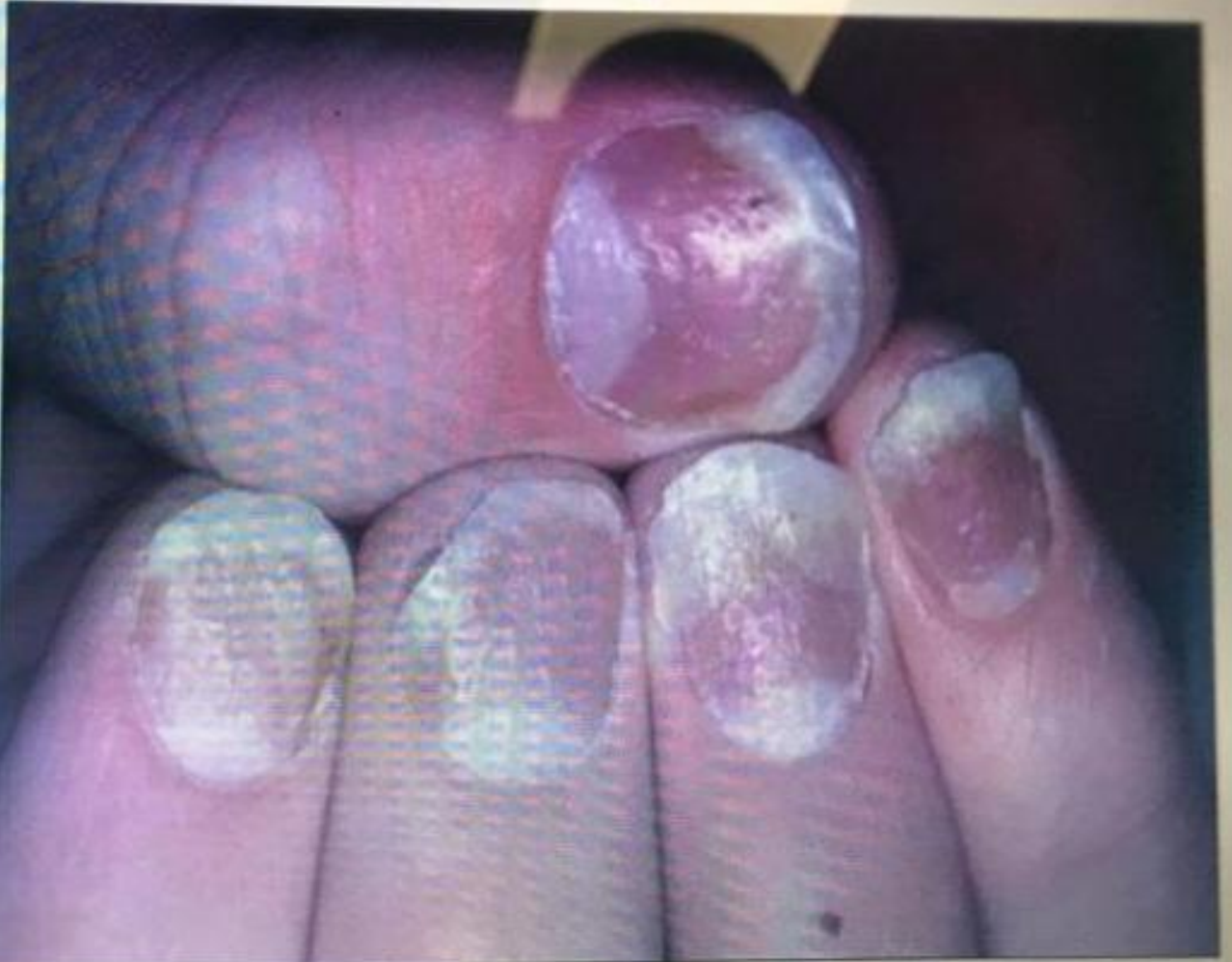



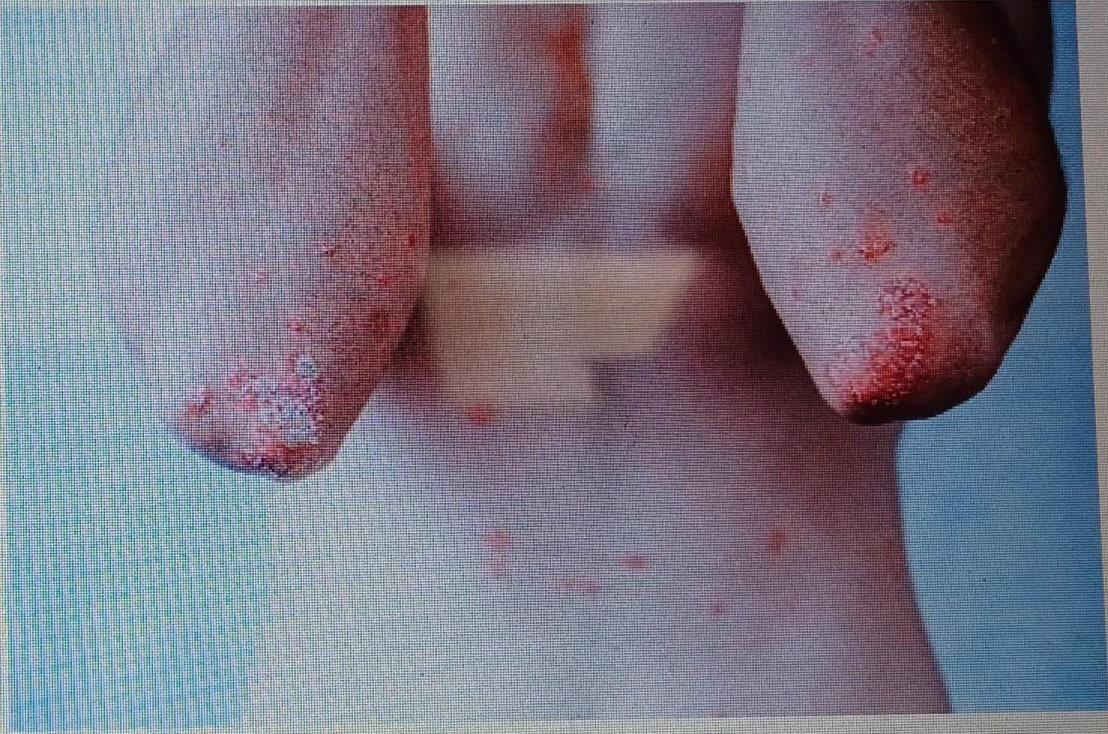acne vulgaris



fingernails psoriasis



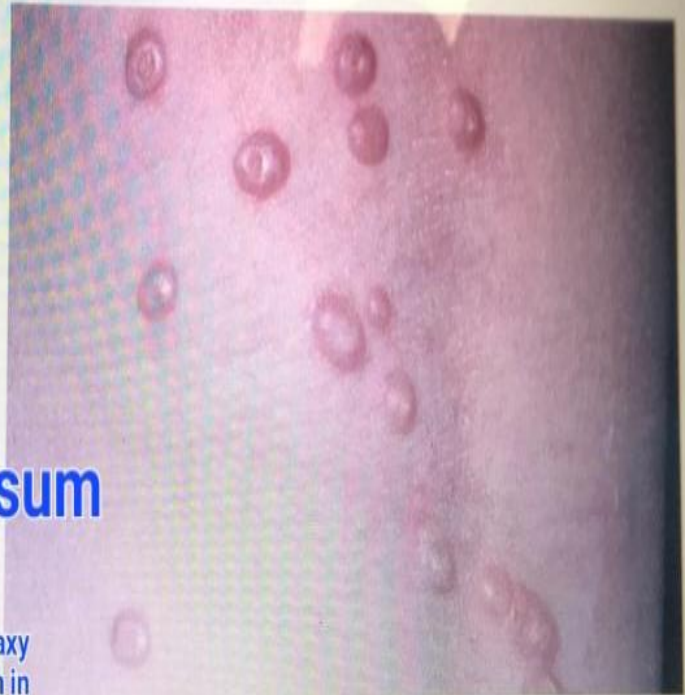psoriasis (not sure)



N9 (1 SCORE)

1) Describe the lesion (0,5 point)

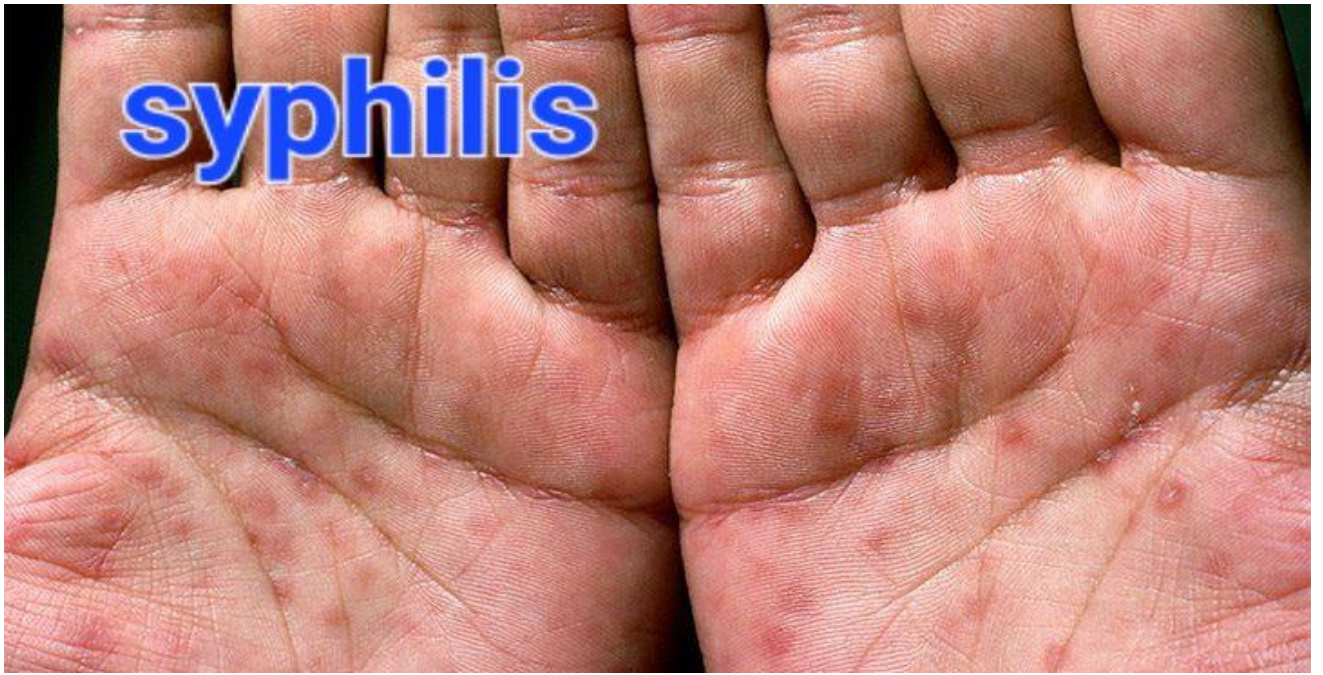
2) Make a diagnose (0,5point)



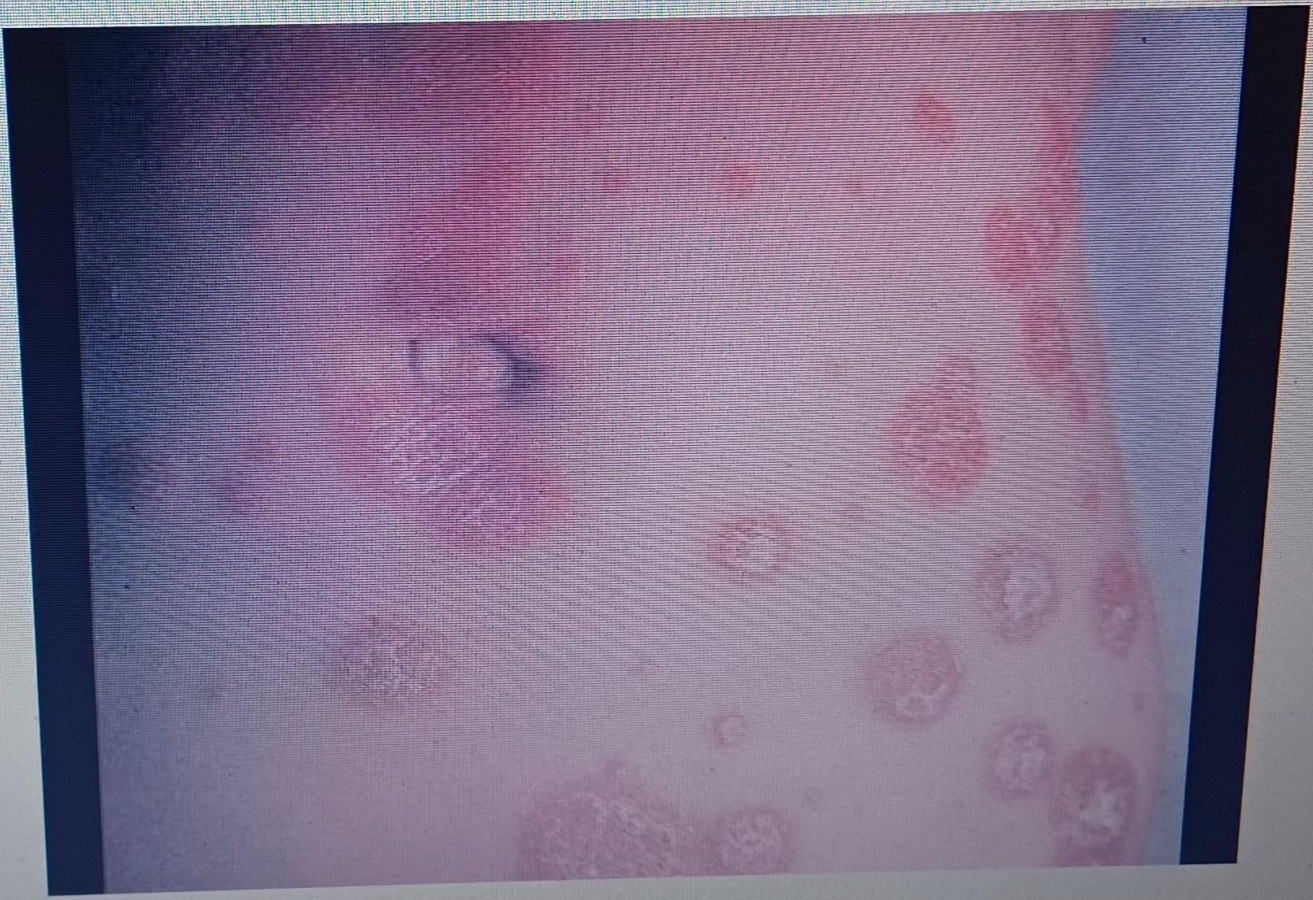Molluscum contagiosum

multiple, rounded, dome-shaped, pink, waxy papules that are 2-5 mm (rarely up to 1.5 cm in the case of a giant molluscum) in diameter. The papules are umbilicated and contain a caseous plug.

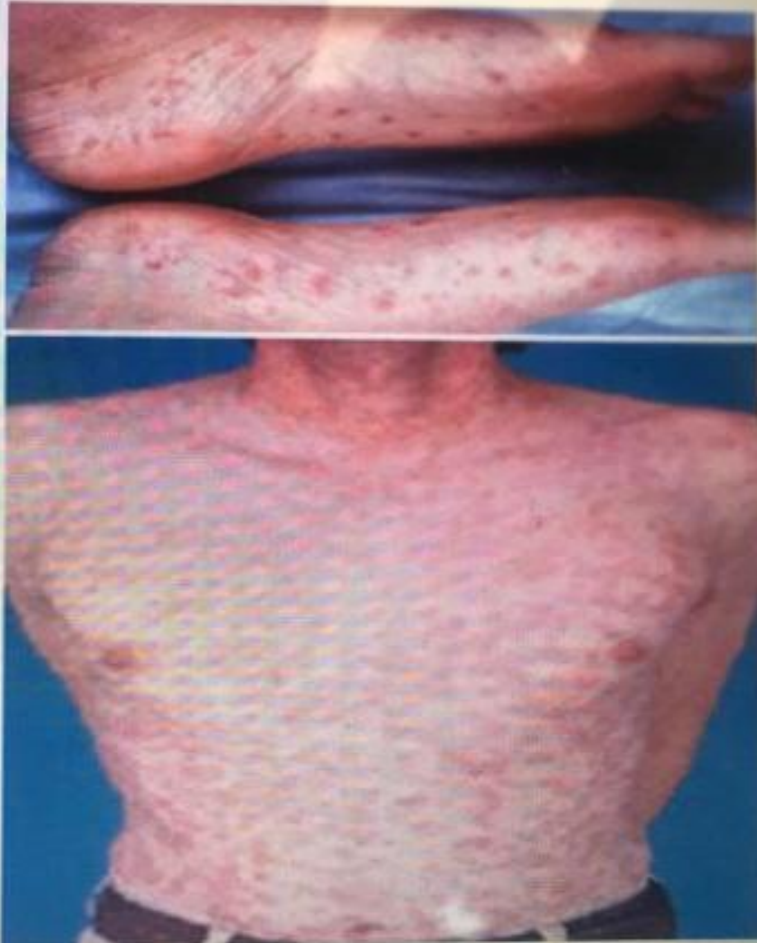syphilis



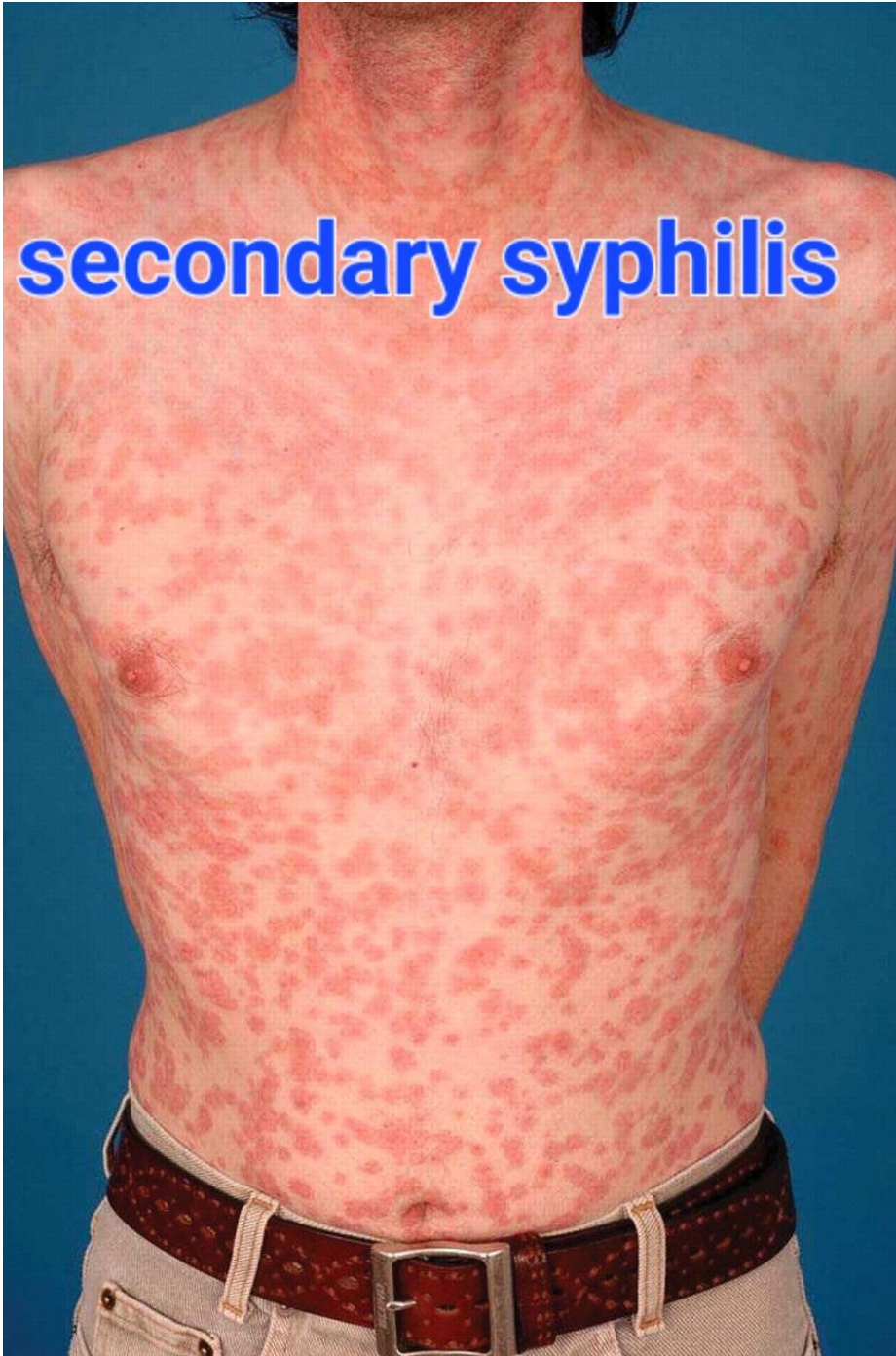psoriasis

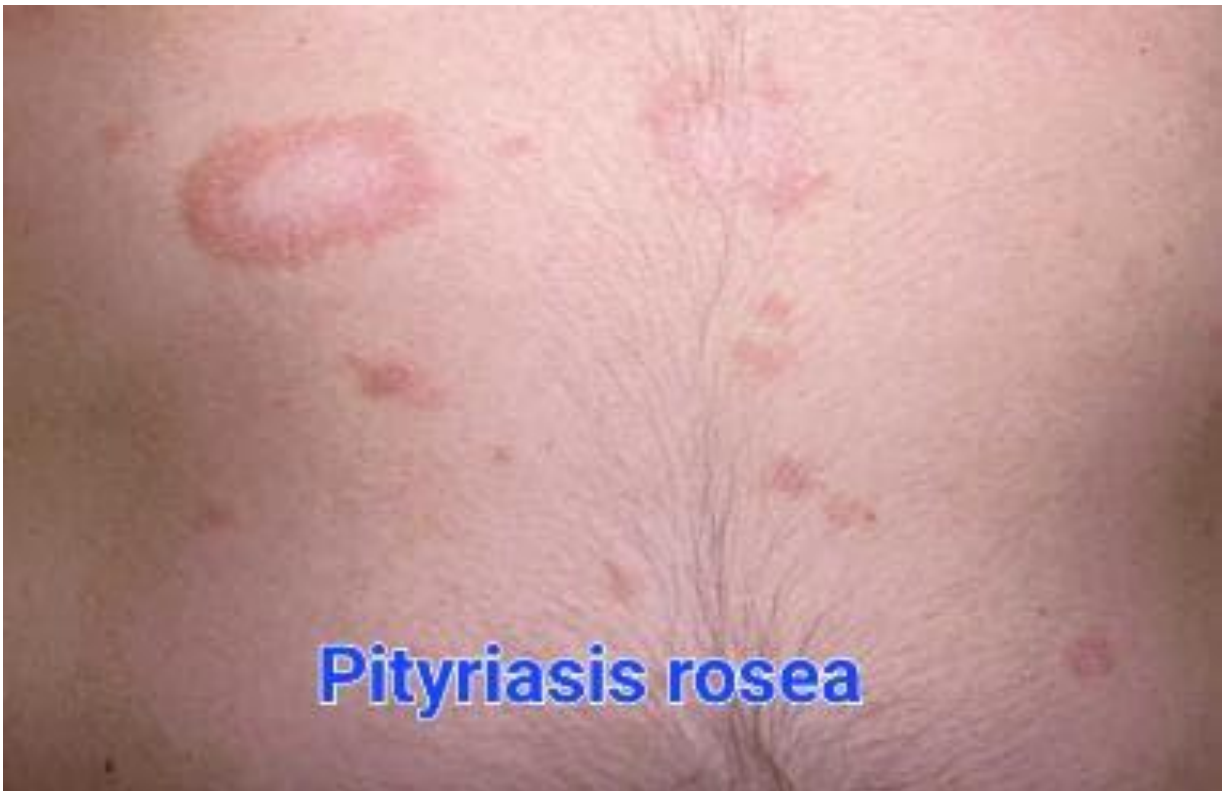
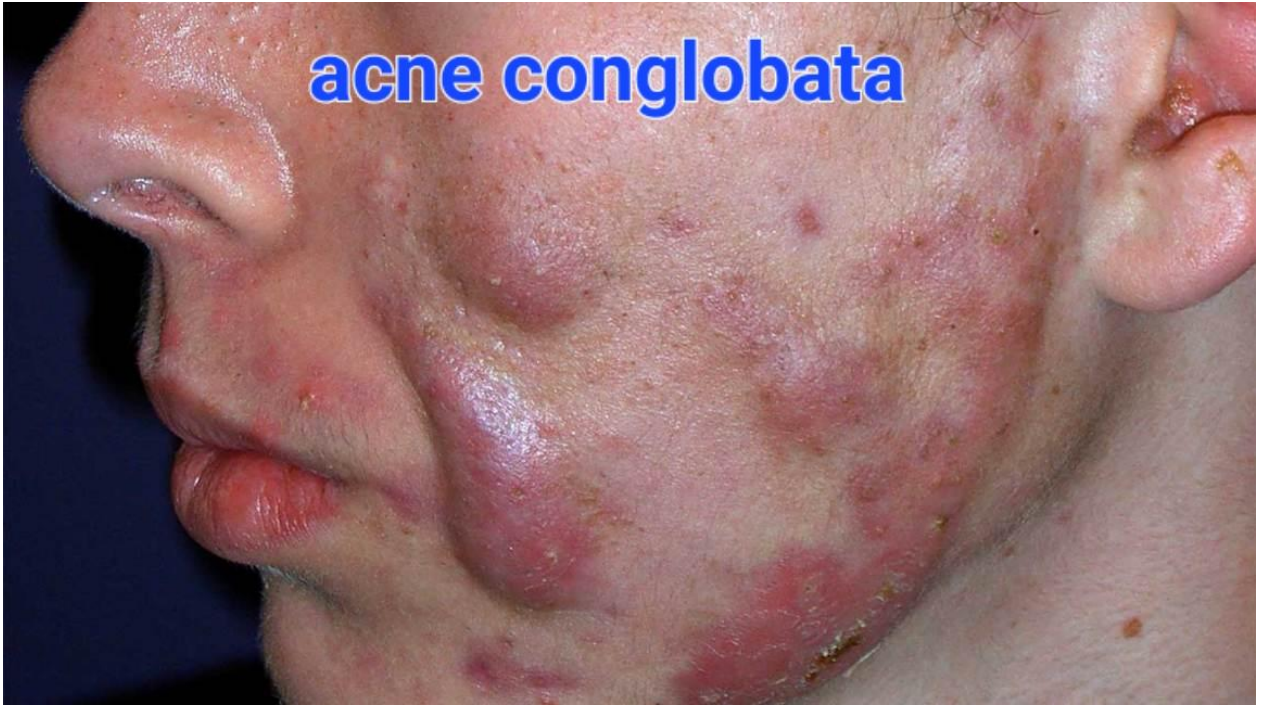
secondary syphilis

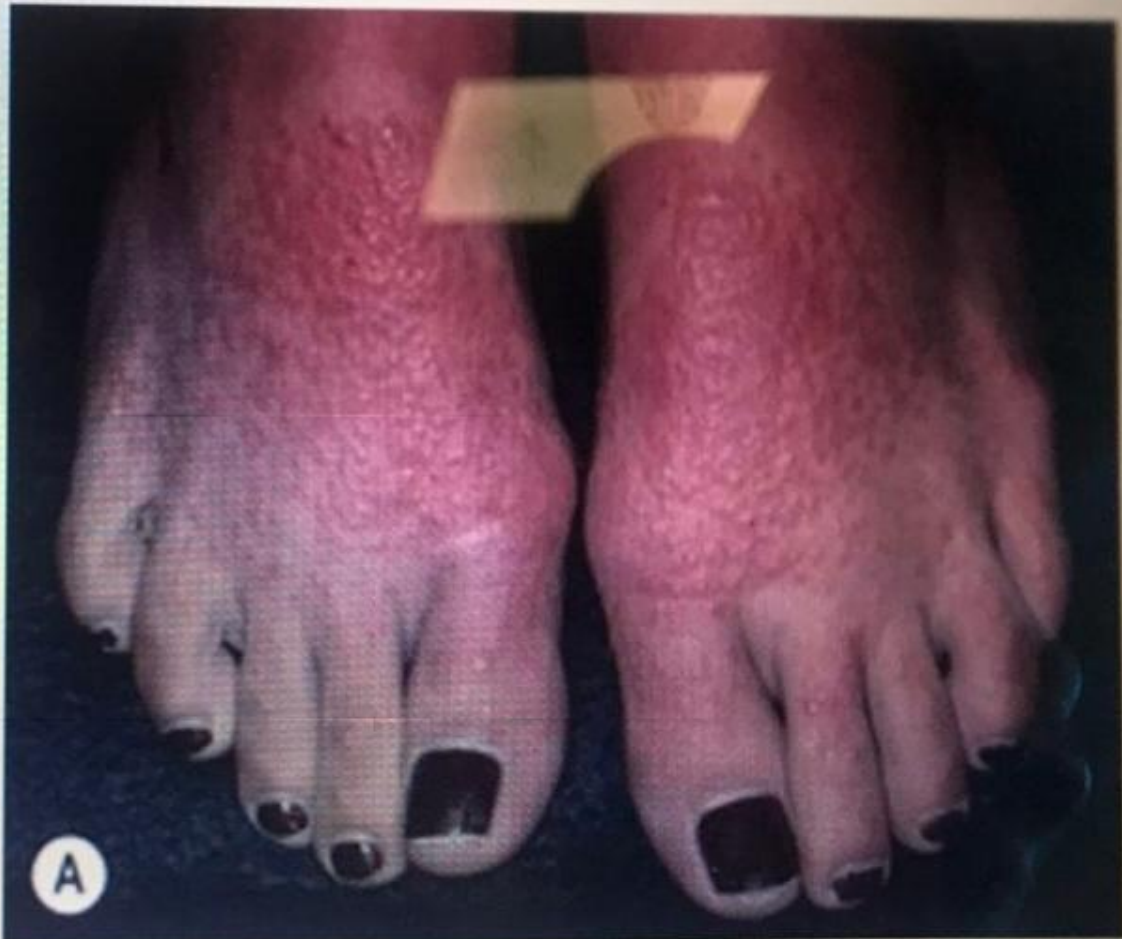

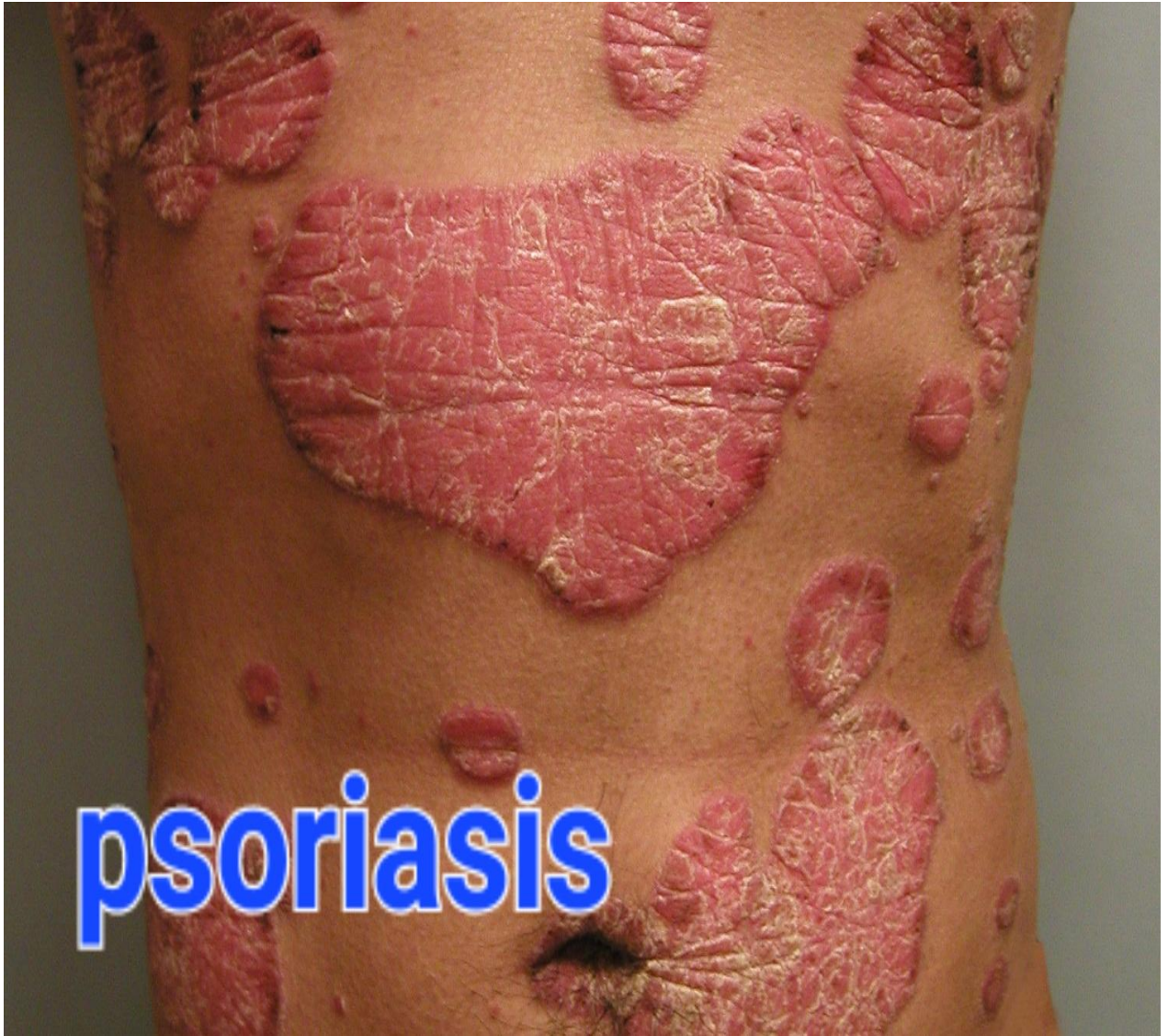secondary syphilis



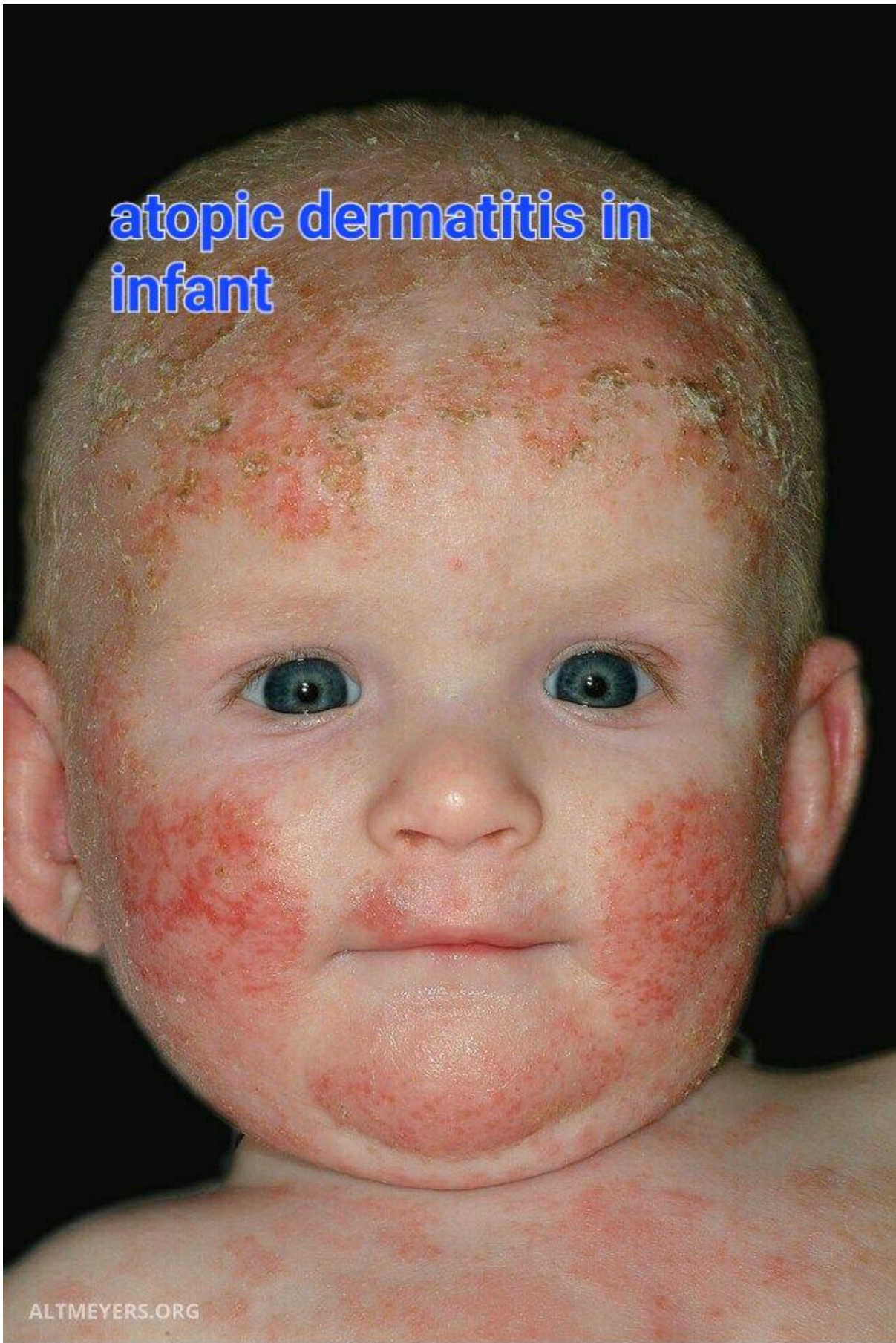

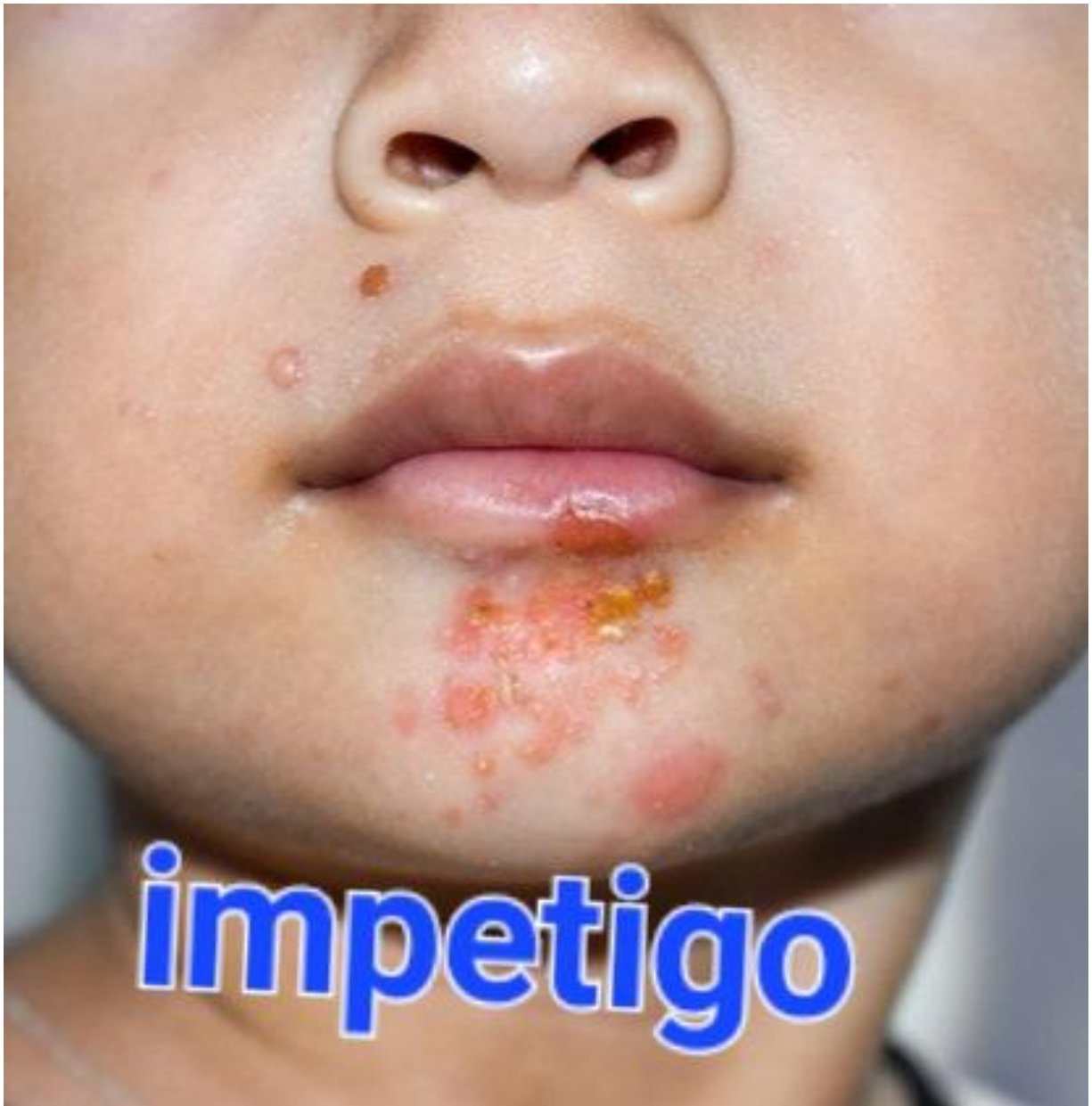allergic contact dermatitis





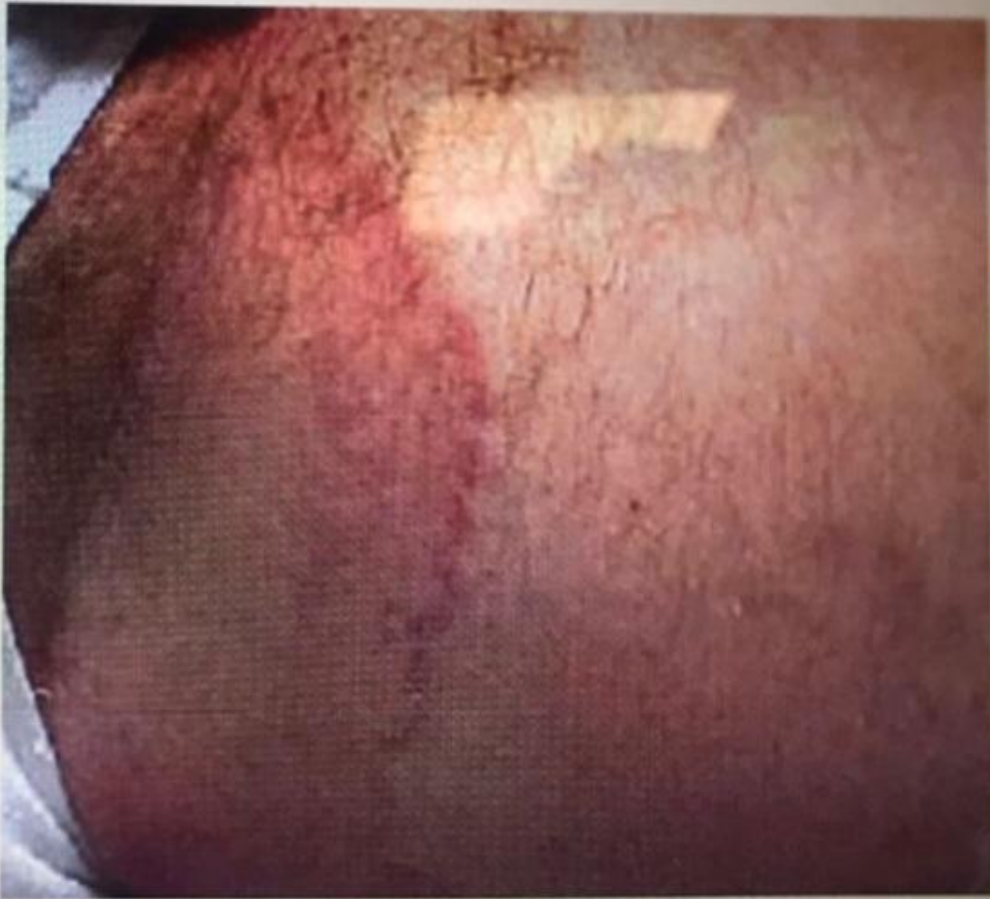**atopic dermatitis in
infant**



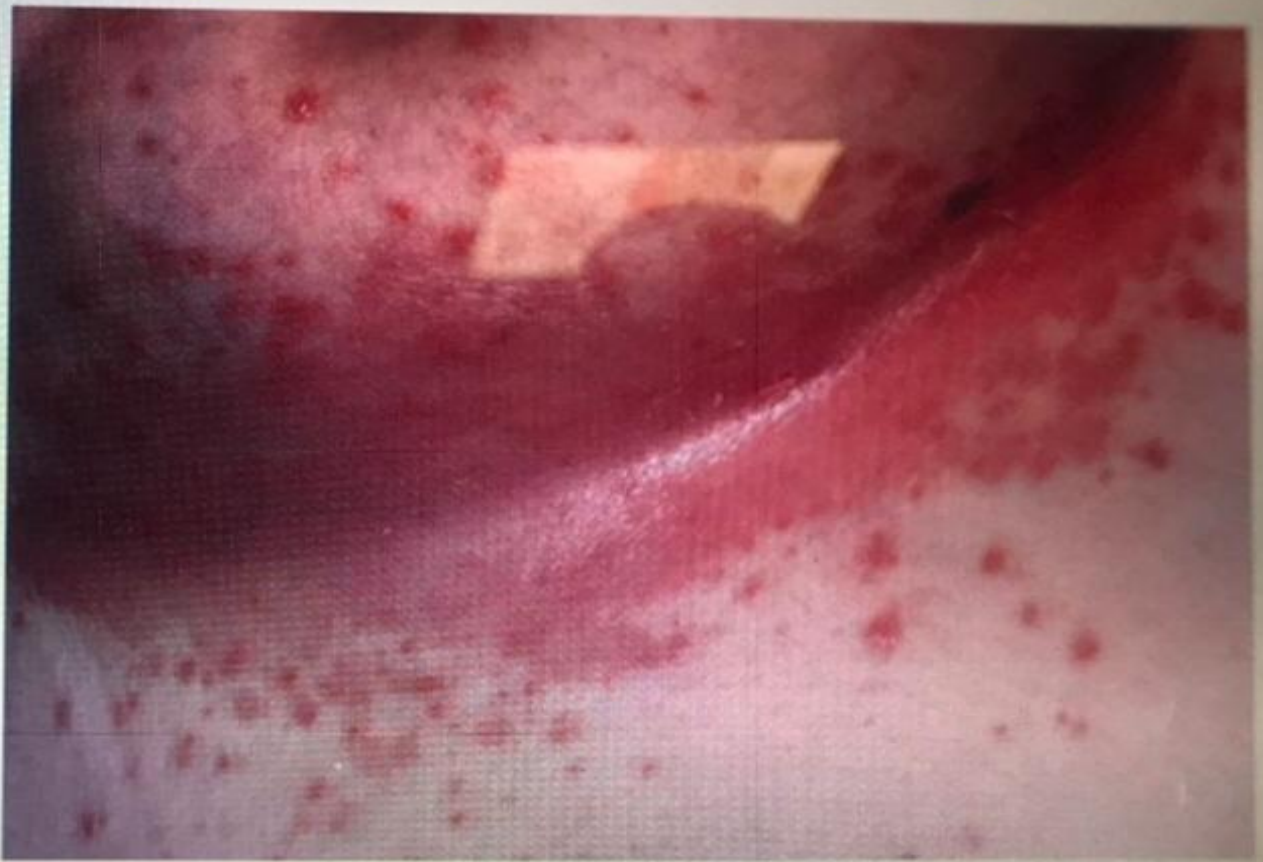

impetigo

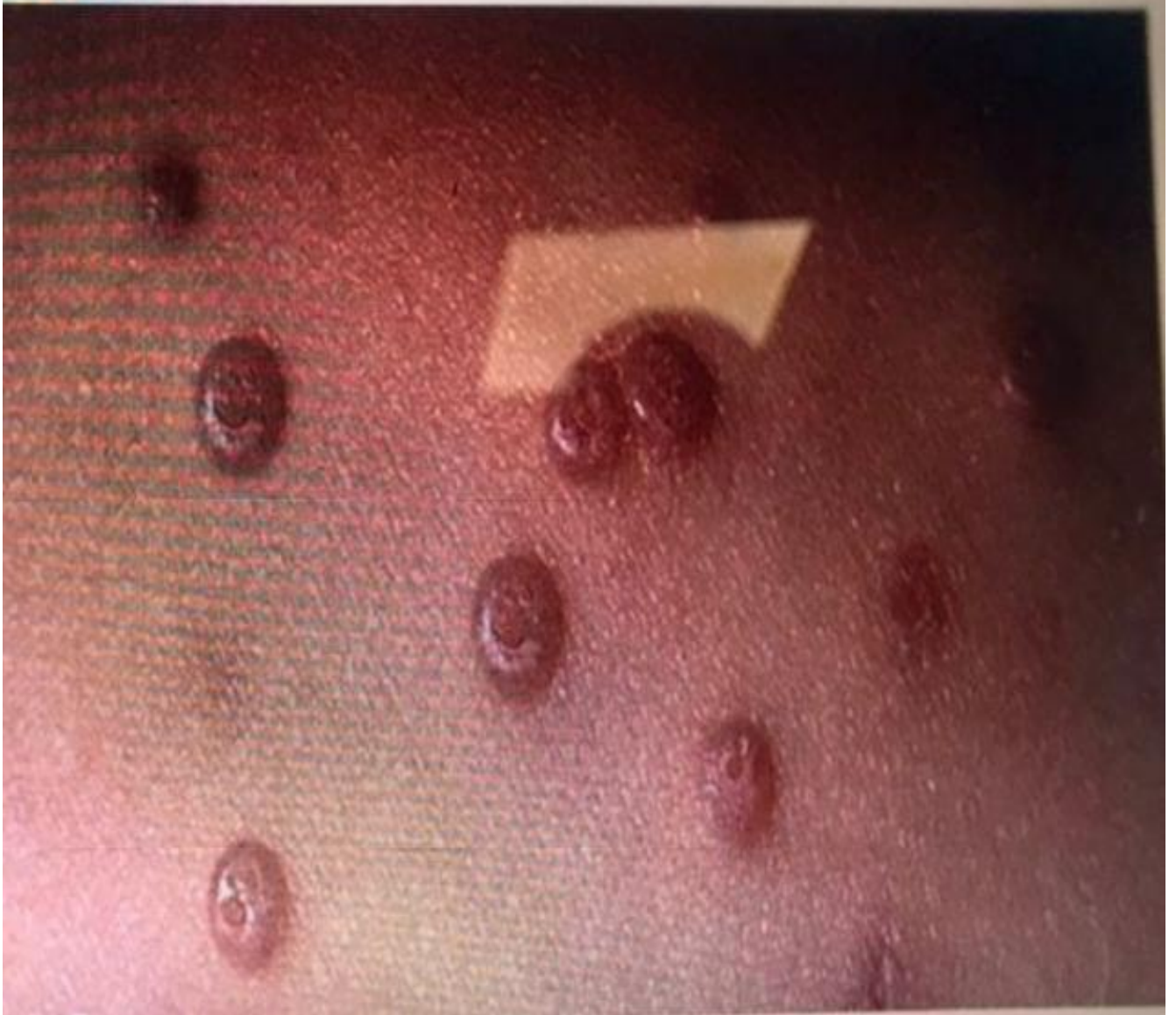tinea cruris (not sure)



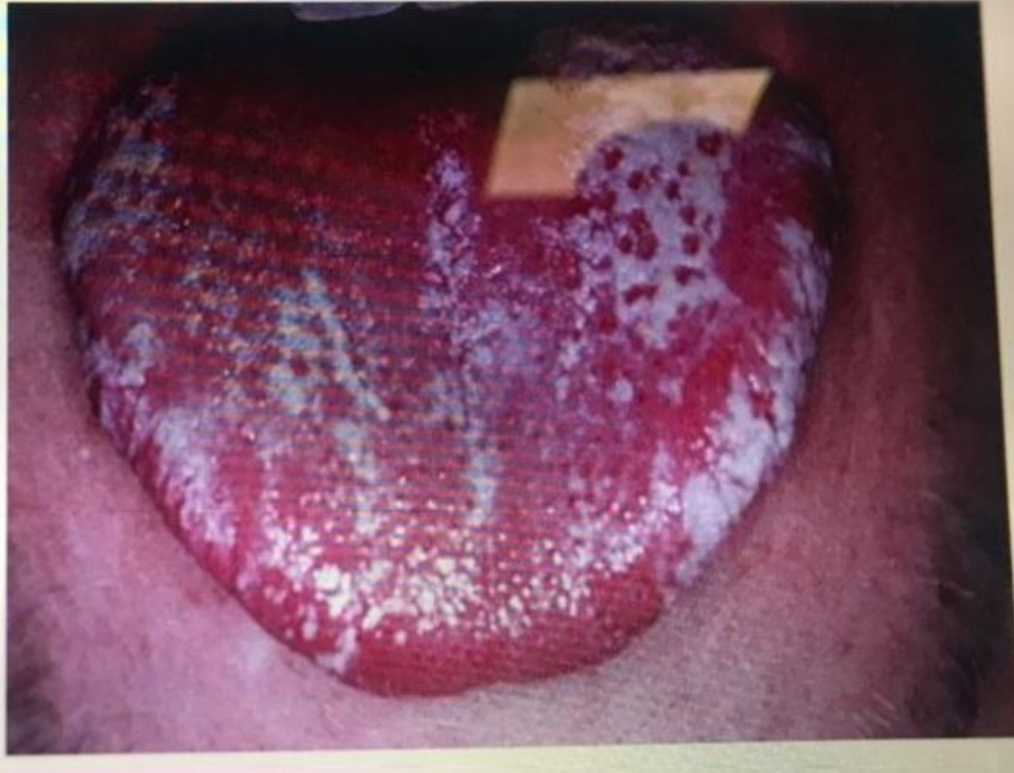Streptococcal intertigo



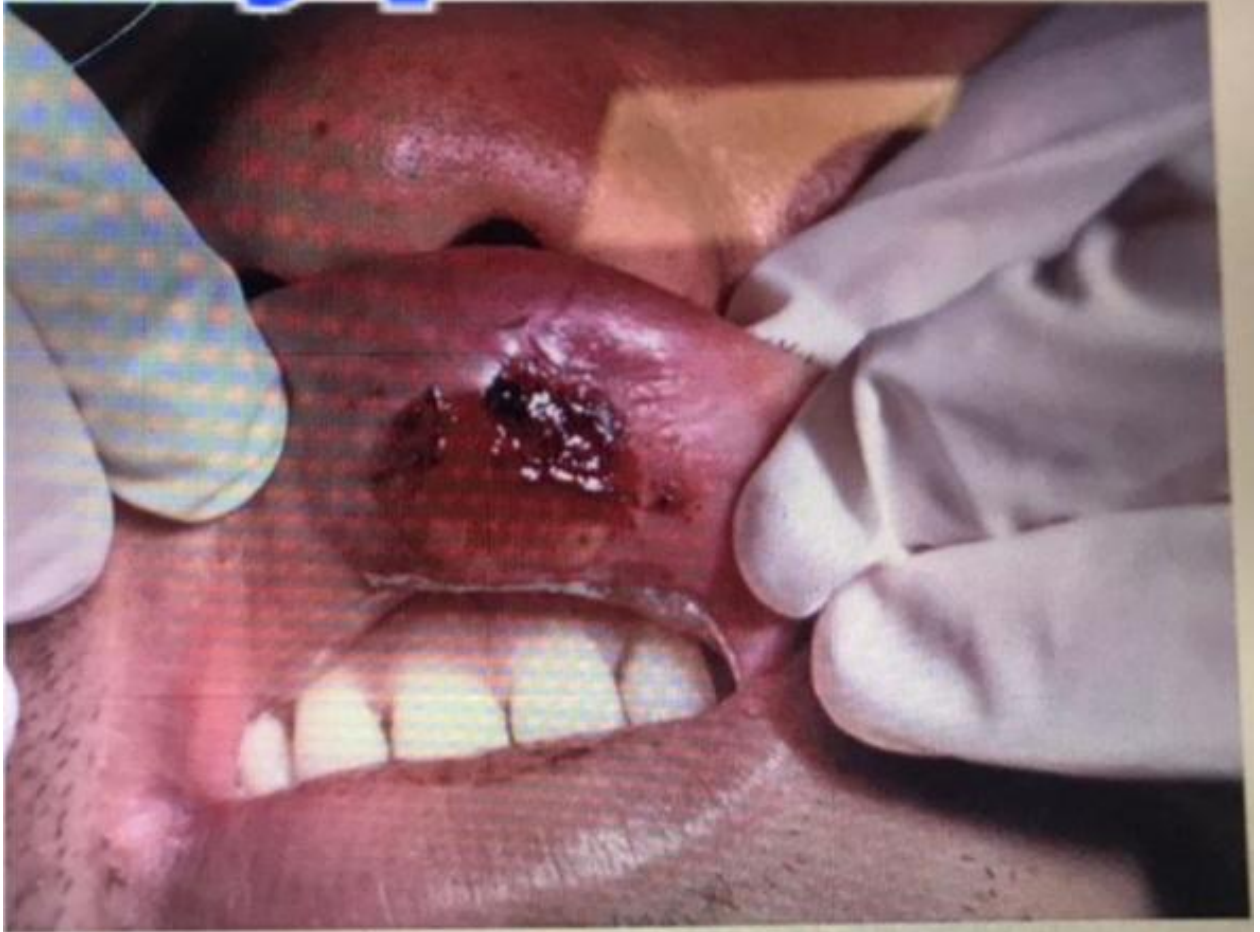Molluscum contagiosum



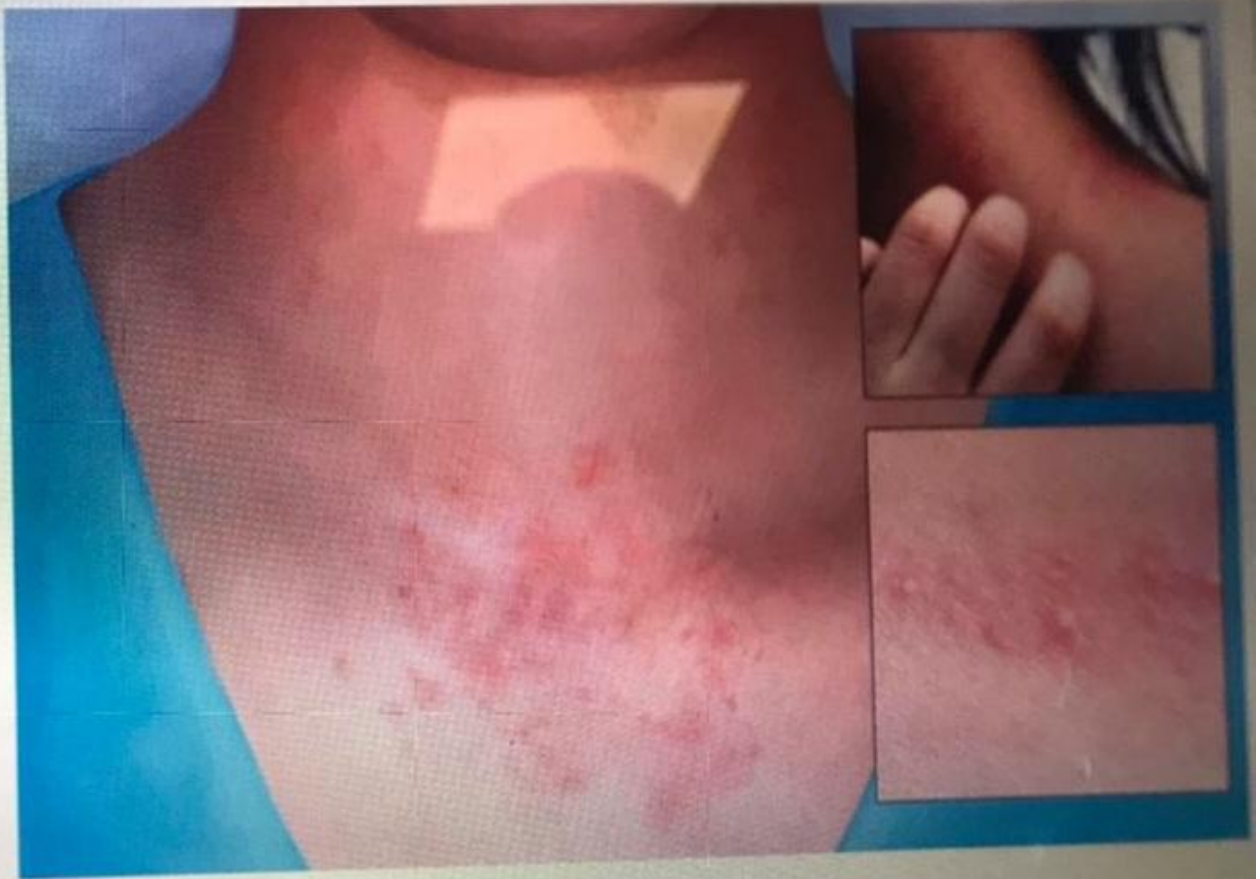oral candidiasis



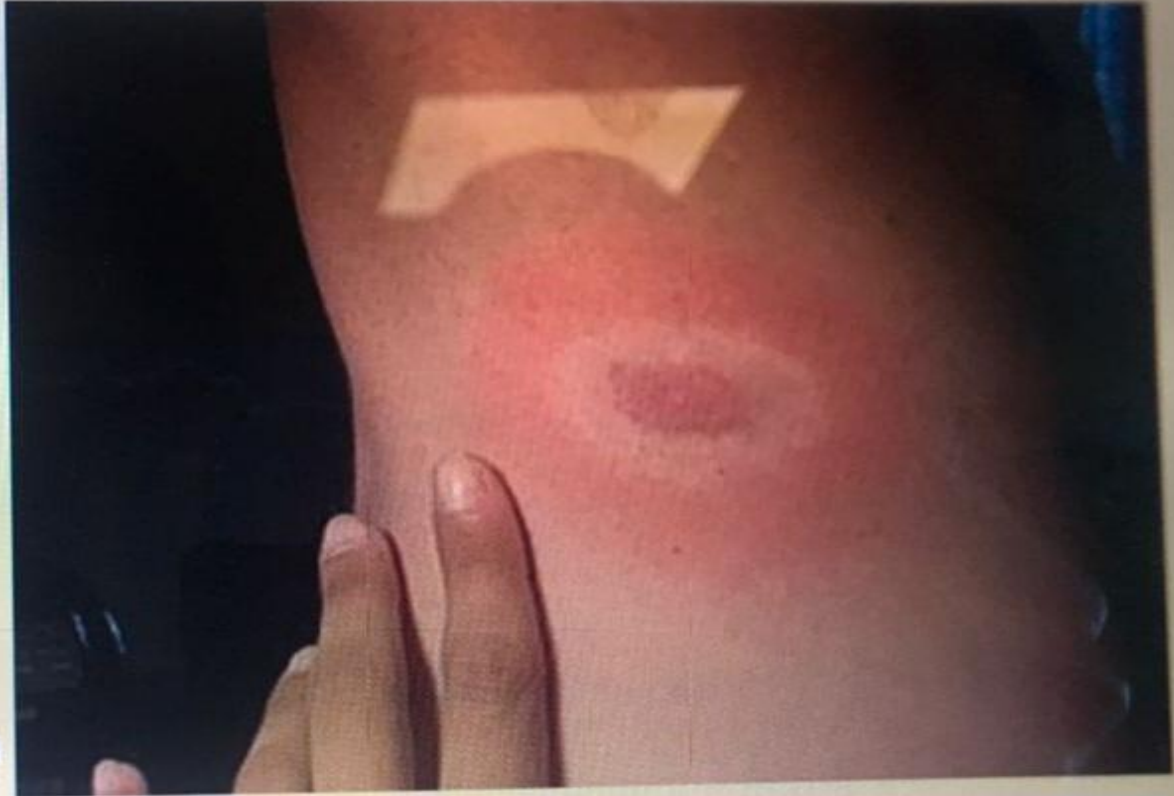syphills

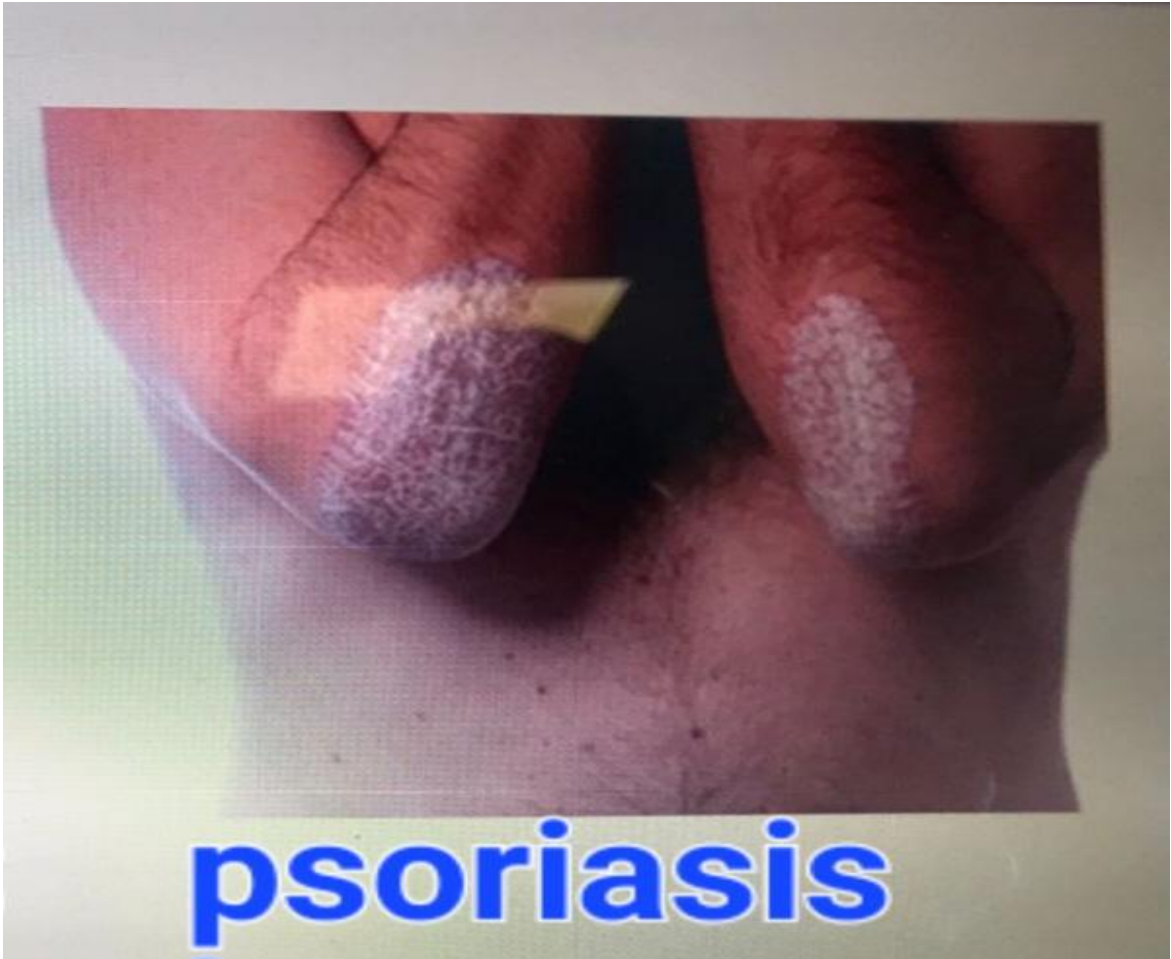


ore) **contact dermatitis**



lyme disease





MIDTERM - CASE - N1 - PowerPoint

Transitions Animations Slide Show Review View Add-ins Help Tell me what you want to do



Font Paragraph Drawing

CASE – N1 (5 score)

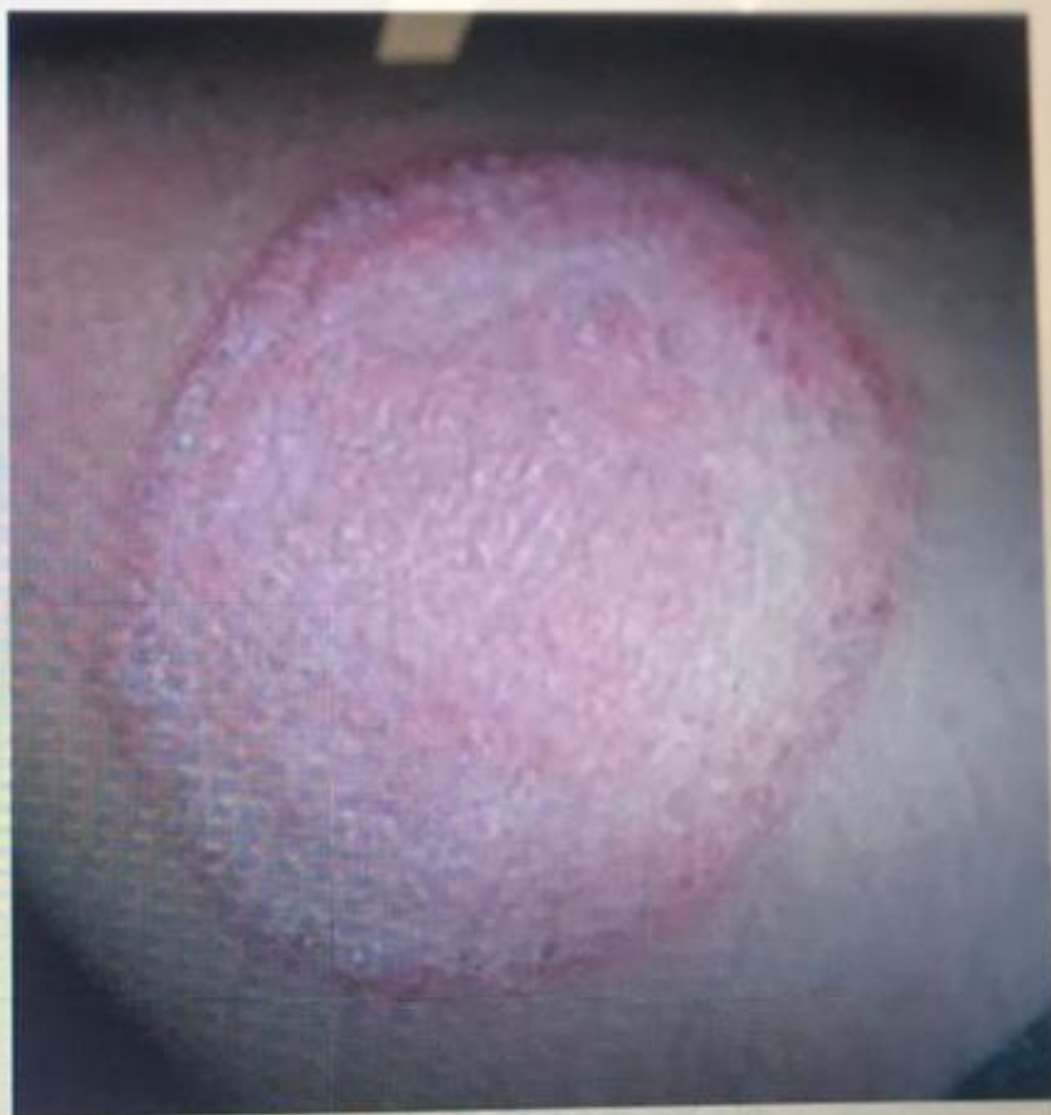**1-year-old baby has eruption on the palms and soles, with distress of sleep.
GBT - slight eosinophilia, mother has the itching - and eruption on the abdomen**

- 1) Primary diagnose
- 2) Differential diagnose
- 3) Lab test
- 4) Final diagnose
- 5) Treatment

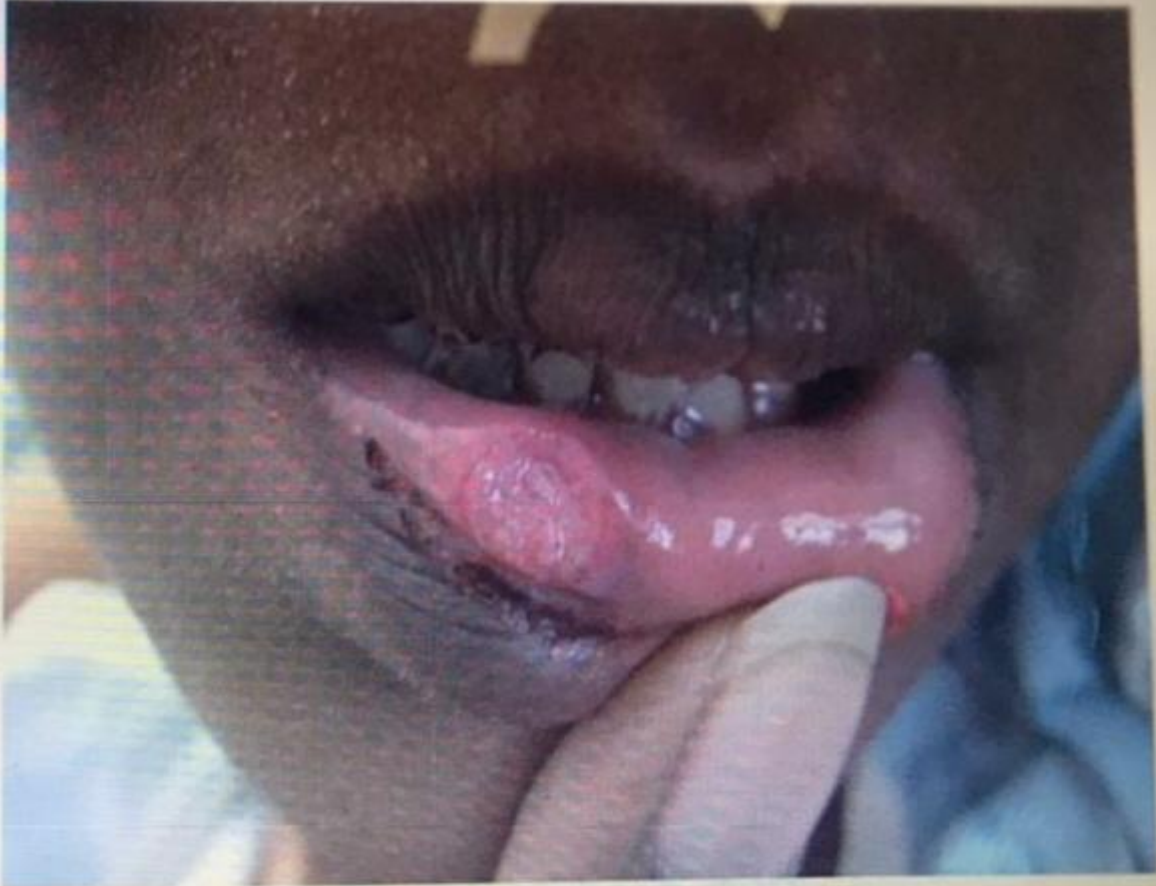scabies



tinea corporis

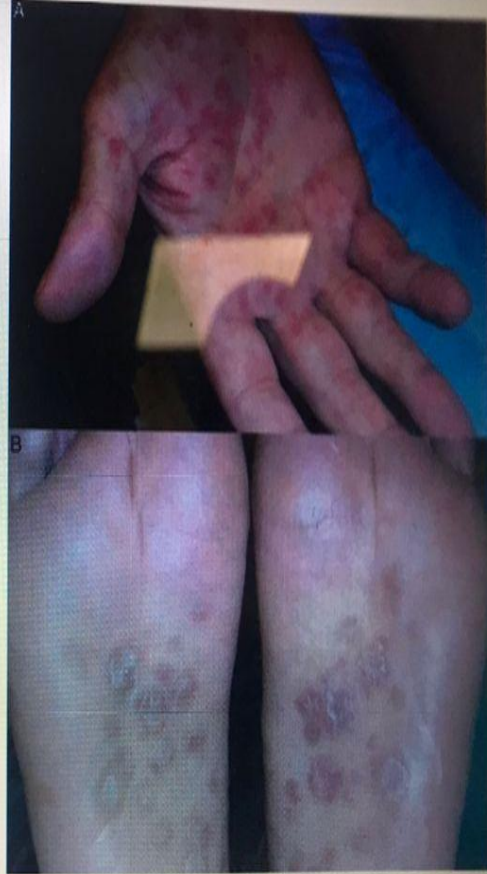

primary syphilis



N10 (1 SCORE)

- 1) Describe the lesion (0,5 point)
- 2) Make a diagnose (0,5point)



**secondary syphilis
(palmoplantar rash)**


I U S abc ↻ Aa - ab - A - Font Paragraph Drawing

Align Text -
Convert to SmartArt -

Arrange
Quick Styles -
Shape Outline -
Shape Effects -

N7 (1 SCORE)

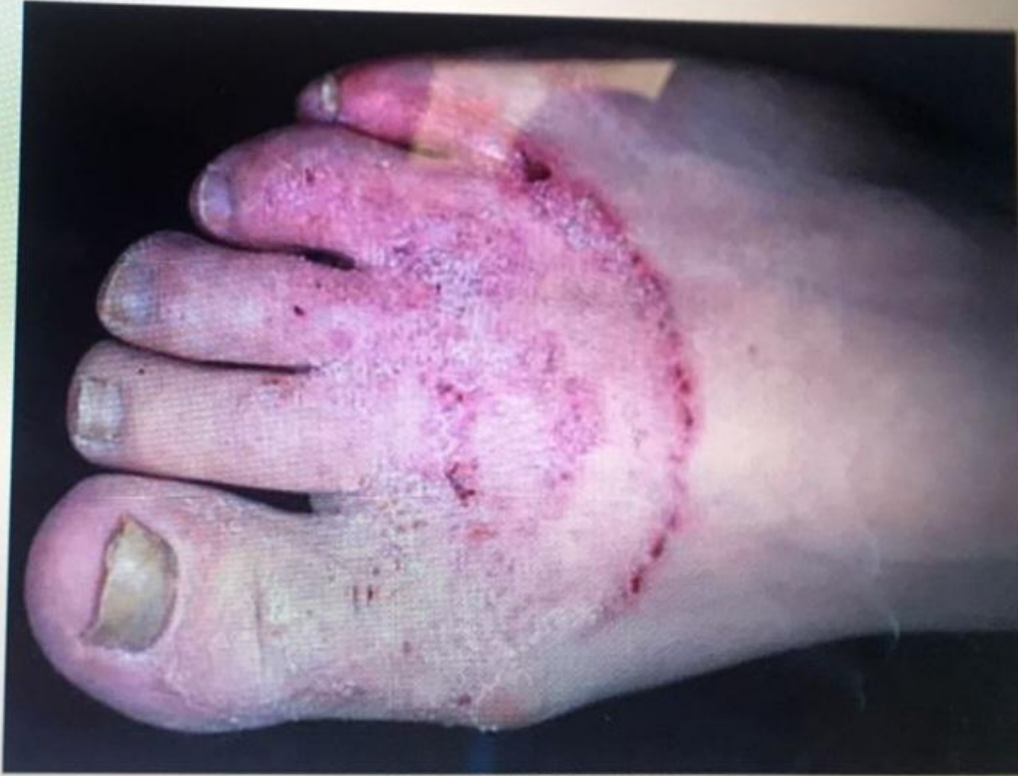- 1) Describe the lesion (0,5 point)
- 2) Make a diagnose (0,5 point)



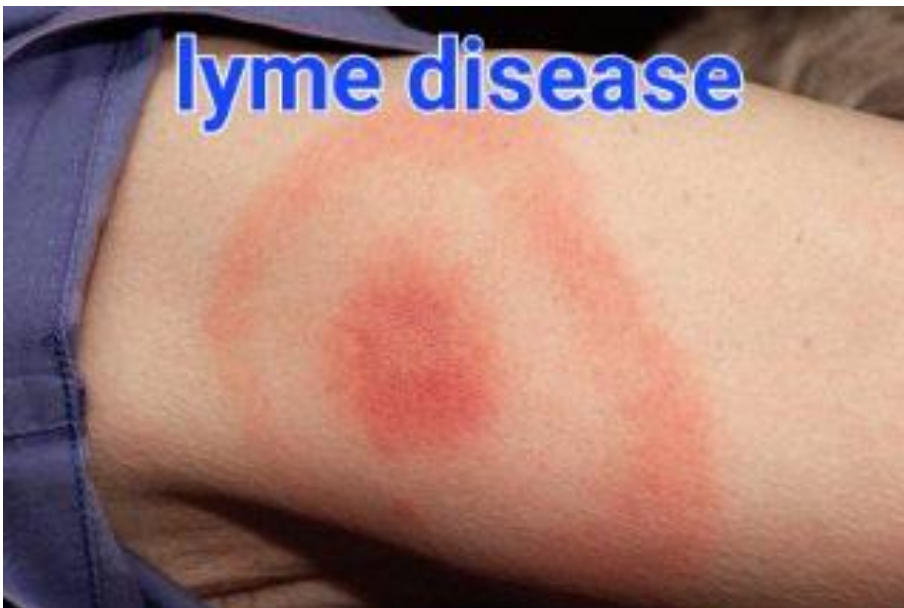**herpes simplex 2
(genital herpes)**

Notes Comments

tinea pedis

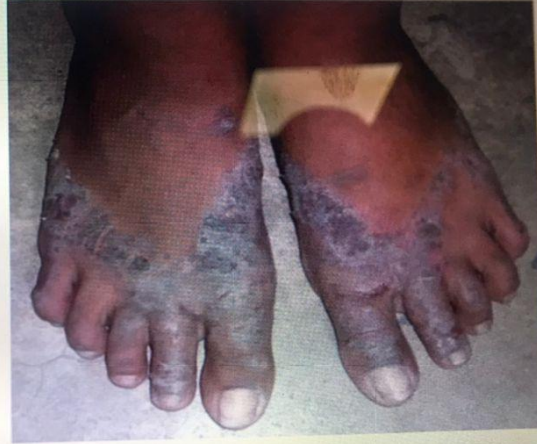

lyme disease



N5 (1 SCORE)

- 1) Describe the lesion (0,5point)
- 2) Make a diagnose (0,5 point)

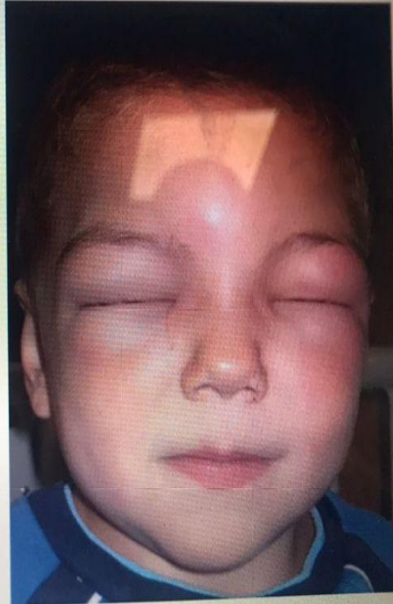


contact dermatitis

N4 (1 SCORE)

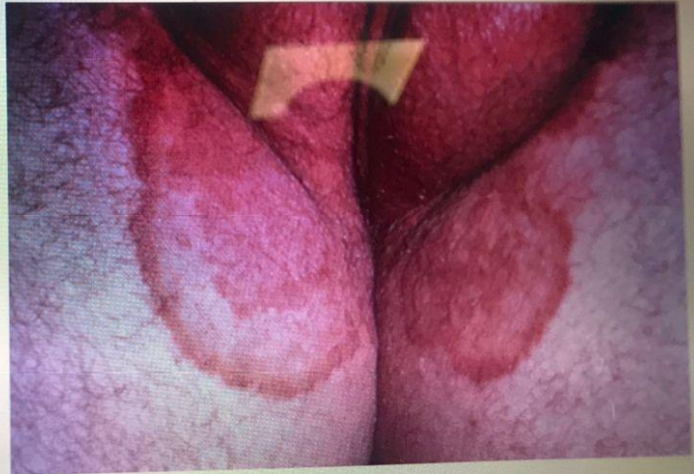
- 1) Describe the lesion (0,5 point)
- 2) Make a diagnose (0,5 point)

angioedema



N2 (1 SCORE)

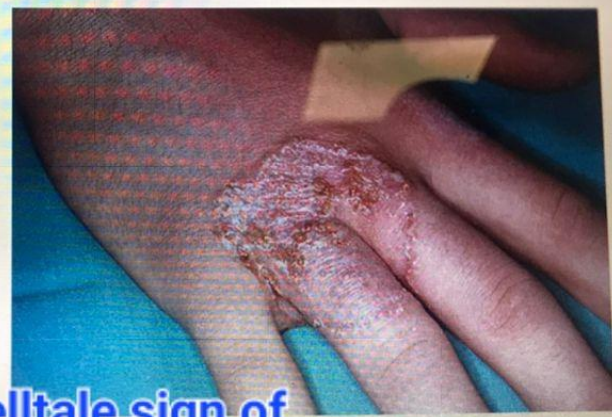- 1) Describe the lesion (0,5point)
- 2) Make a diagnose (0,5 point)



intertrigo

N8 (1 SCORE) Ringworm is a common skin infection otherwise known as tinea. It is caused by a fungus.

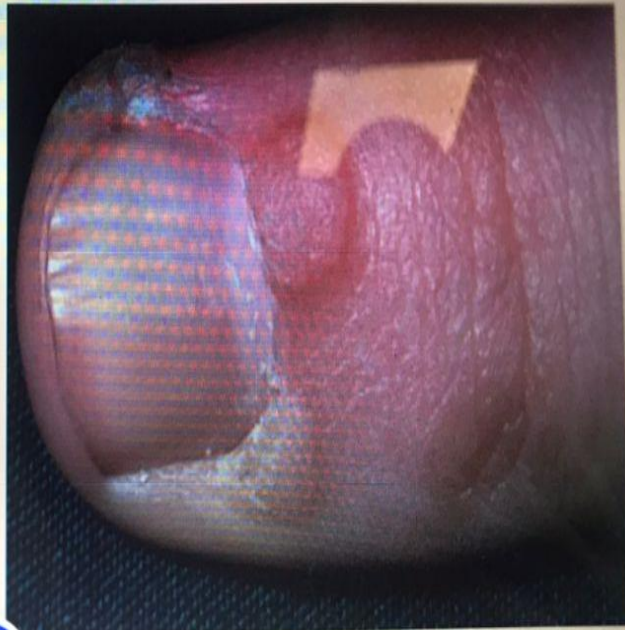- 1) Describe the lesion (0,5 point)
- 2) Make a diagnose (0,5 point)



tinea manuum- The telltale sign of ringworm is a red, scaly patch or bump that itches. Over time, the bump turns into a ring- or circle-shaped patch.

N10 (1 SCORE)

- 1) Describe the lesion (0,5 point)
- 2) Make a diagnose (0,5point)




warts

itions Animations Slide Show Review View Add-ins Help Tell me what you want to do

Font Paragraph Drawing

N6(1 SCORE)

- 1) Describe the lesion (0,5 point)
- 2) Make a diagnose (0,5 point)



Tinea nigricans


Notes Comments

itions Animations Slide Show Review View Add-ins Help Tell me what you want to do

Font Paragraph Drawing

N7 (1 SCORE)

- 1) Describe the lesion (0,5 point)
- 2) Make a diagnose (0,5 point)



scabies


Notes Comments

itions Animations Slide Show Review View Add-ins Help Tell me what you want to do

Font Paragraph Drawing

N4 (1 SCORE)

1) Describe the lesion (0,5 point)
2) Make a diagnose (0,5 point)




Lichen planus

Notes Comments

Font Paragraph Drawing

N3 (1 SCORE)

- 1) Describe the lesion (0,5 point)
- 2) Make a diagnose (0,5 point)



Pityriasis rosae



Notes Comments

Font Paragraph Drawing

CASE – N1 (5 score)

Patient 35 years man has suddenly onset eruption and intensive rush during 1 day which spreads on the body. 3 hours ago arise the swelling around the eye.

- 1) Primary diagnose
- 2) Differential diagnose
- 3) Lab test
- 4) Final diagnose
- 5) Treatment




urticaria + angioedema

Notes Comments

N8 (1 SCORE)

- 1) Describe the lesion (0,5 point)
- 2) Make a diagnose (0,5 point)

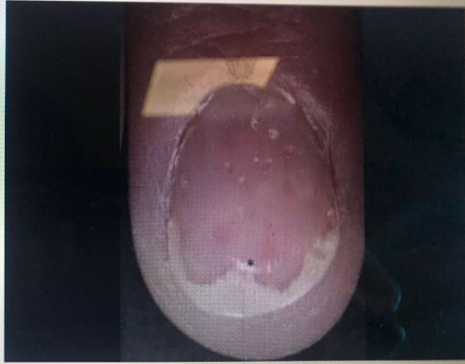


warts (common wart).

The image shows a close-up of a human hand with a common wart on the side of a finger. The wart is a small, raised, cauliflower-like growth with a rough, scaly surface. The surrounding skin appears normal. The image is presented within a software interface with a menu bar at the top containing options like 'Font', 'Paragraph', and 'Drawing'. Below the image, the text 'warts (common wart).' is written in a large, blue, bold font.

N6(1 SCORE)

- 1) Describe the lesion (0,5 point)
- 2) Make a diagnose (0,5 point)




nail psoriasis

The image shows a close-up of a thumb with nail psoriasis. The nail plate is thickened, discolored with white and yellow patches, and has irregular, pitted areas. The surrounding skin is also affected, showing redness and small bumps. The image is presented within a software interface with a menu bar at the top containing options like 'Font', 'Paragraph', and 'Drawing'. Below the image, the text 'nail psoriasis' is written in a large, red, bold font.

Font Paragraph Drawing

N6 (1 SCORE)

- 1) Describe the lesion (0,5 point)
- 2) Make a diagnose (0,5 point)




lichen planus (oral)

Notes Comments

Font Paragraph Drawing

N8 (1 SCORE)

- 1) Describe the lesion (0,5 point)
- 2) Make a diagnose (0,5 point)




warts (Mosaic Wart).

Notes Comments

B I U S abc AV - Aa - ab - A - Font Paragraph Drawing

N10 (1 SCORE)

- 1) Describe the lesion (0,5 point)
- 2) Make a diagnose (0,5point)



Streptococcal intertrigo

Notes Comments


Taskbar icons: File Explorer, Edge, Teams, etc.

Help Tell me what you want to do

B I U S abc AV - Aa - ab - A - Font Paragraph Drawing

N1 (1 SCORE)

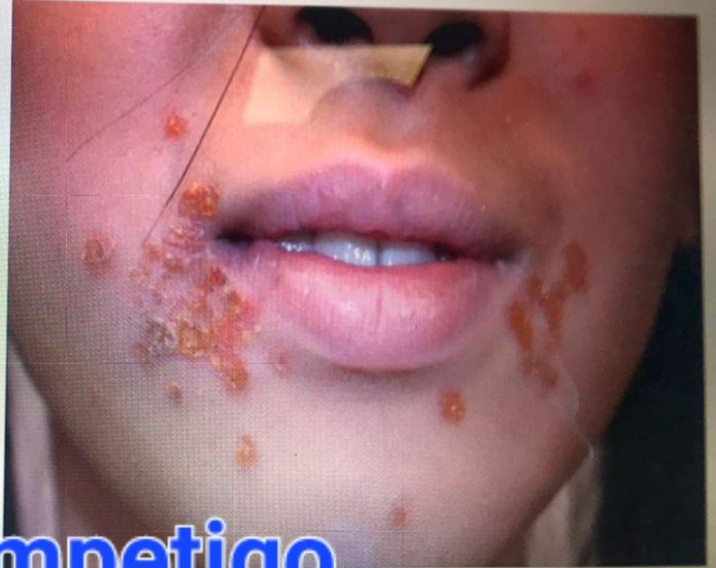- 1) Describe the lesion (0,5 point)
- 2) Make a diagnose (0,5 point)



intertigo

N2 (1 SCORE)

- 1) Describe the lesion (0,5point)
- 2) Make a diagnose (0,5 point)

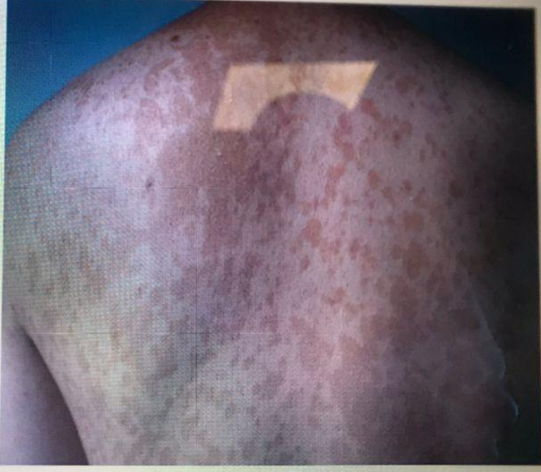


non bullous impetigo

Font Paragraph Drawing

N9 (1 SCORE)

- 1) Describe the lesion (0,5 point)
- 2) Make a diagnose (0,5point)



Pityriasis (tinea) versicolor


Notes Comments

Font Paragraph Drawing

CASE – N1 (5 score)

Patient 32 years old men has eruption on the penis during 4 days. Status localis – small painless erosion with elevated border, serological rapid test RPR is negative

- 1) Primary diagnose
- 2) Differential diagnose
- 3) Lab test
- 4) Final diagnose
- 5) Treatment



Primary Syphilis (chancre)

Notes Comments


Taskbar icons: File Explorer, Edge, Chrome, Teams, Word

B I U S abc AV - Aa - aly - A - [] Align Text - [] Convert to SmartArt - [] Arrange [] Quick Styles - [] Shape Effects

Font Paragraph Drawing

N1 (1 SCORE)

1) Describe the lesion (0,5 point)
2) Make a diagnose (0,5 point)



psoriasis


Notes Comments [] [] [] []

B I U S abc AV - Aa - aly - A - [] Align Text - [] Convert to SmartArt - [] Arrange [] Quick Styles - [] Shape Effects

Font Paragraph Drawing

N2 (1 SCORE)

1) Describe the lesion(0,5point)
2) Make a diagnose (0,5 point)

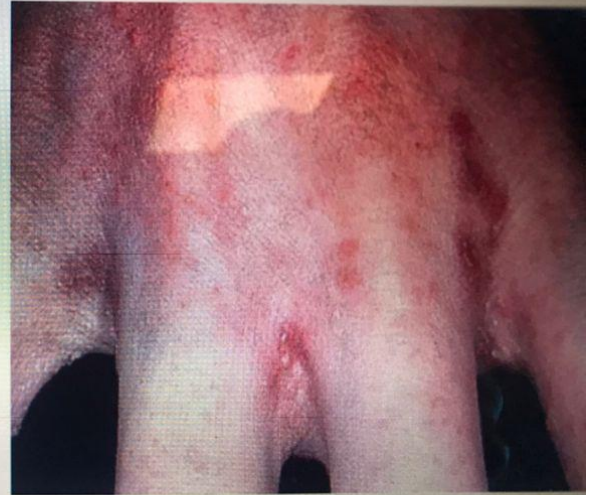

**Pityriasis rosae –
“Christmas tree” pattern**

Notes Comments [] [] [] []

N3 (1 SCORE)

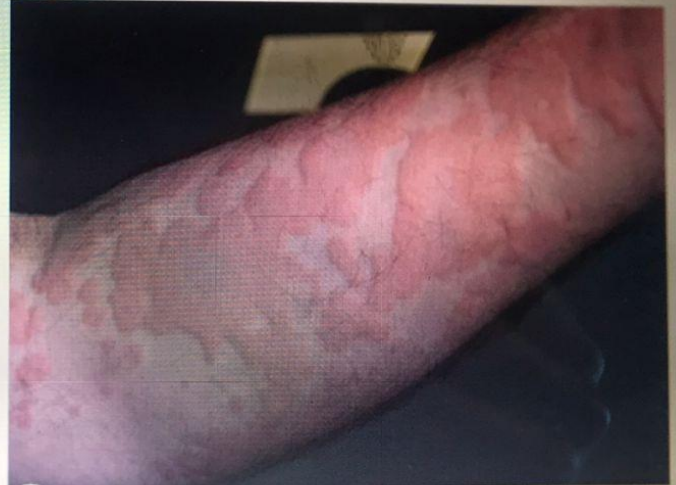- 1) Describe the lesion (0,5 point)
- 2) Make a diagnose (0,5 point)



scabies

N5 (1 SCORE)


- 1) Describe the lesion (0,5point)
- 2) Make a diagnose (0,5 point)



urticaria

N4 (1 SCORE)


- 1) Describe the lesion (0,5 point)
- 2) Make a diagnose (0,5 point)



secondary syphilis

N8 (1 SCORE)

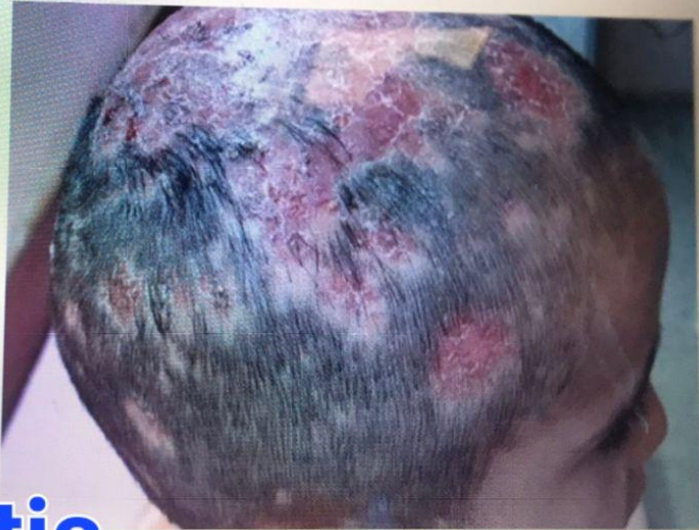- 1) Describe the lesion (0,5 point)
- 2) Make a diagnose (0,5 point)



herpes simplex type 1

N5 (1 SCORE)

- 1) Describe the lesion (0,5point)
- 2) Make a diagnose (0,5 point)




tinea capitis

Animations Slide Show Review View Add-ins Help Tell me what you want to do

Font Paragraph Drawing

N4 (1 SCORE)

1) Describe the lesion (0,5 point)
2) Make a diagnose (0,5 point)




pitted keratolysis

Font Paragraph Drawing

N3 (1 SCORE)

- 1) Describe the lesion (0,5 point)
- 2) Make a diagnose (0,5 point)



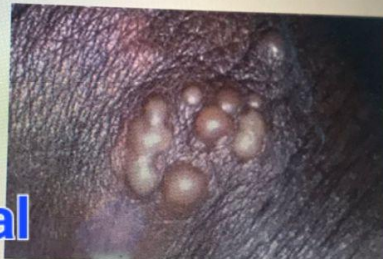

demographia (a form of urticaria).

Font Paragraph Drawing

CASE – N1 (5 score)

Patient - 35 years old male has lymphadenopathy on groin areas - bilateral, a lot of 3 vesicles, one erosion, patient's complains are the feeling of burning, slight itching and discomfort during the urination

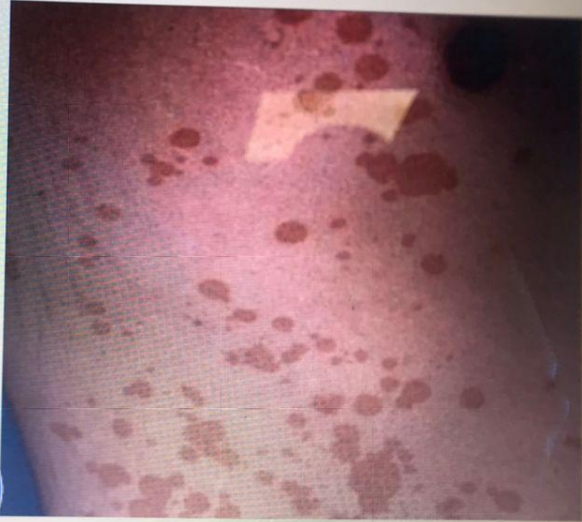- 1) Primary diagnose
- 2) Differential diagnose
- 3) Lab test
- 4) Final diagnose
- 5) Treatment



herpes simplex 2(genital herpes)

N9 (1 SCORE)

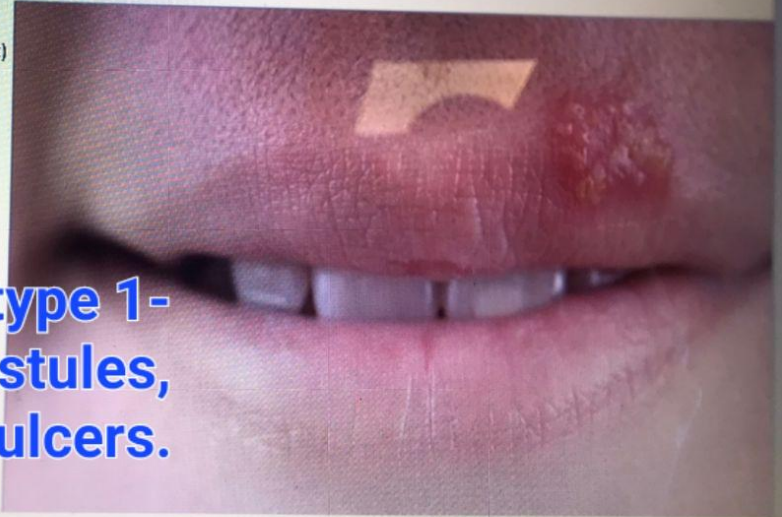- 1) Describe the lesion (0,5 point)
- 2) Make a diagnose (0,5point)



**Pityriasis (tinea)
versicolor**

N7 (1 SCORE)

- 1) Describe the lesion (0,5 point)
- 2) Make a diagnose (0,5 point)




**herpes simplex type 1-
papules, pustules,
vesicles and ulcers.**

Transitions Animations Slide Show Review View Add-ins Help Tell me what you want to do

Font Paragraph Drawing

N5 (1 SCORE)

1) Describe the lesion (0,5point)
2) Make a diagnose (0,5 point)



Tinea pedis(not sure).


Notes

Transitions Animations Slide Show Review View Add-ins Help Tell me what you want to do

Font Paragraph Drawing

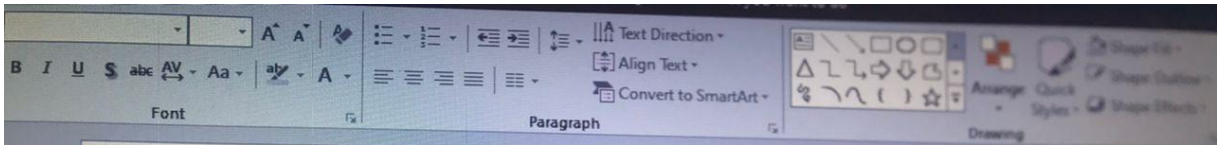
N4 (1 SCORE)

1) Describe the lesion (0,5 point)
2) Make a diagnose (0,5 point)



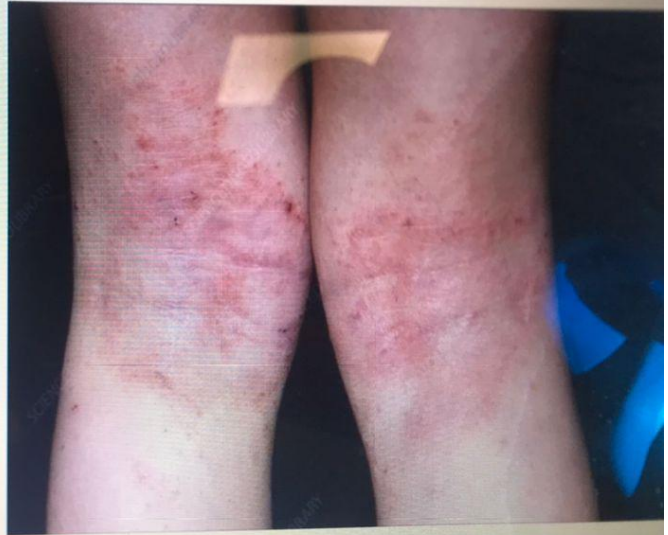onychomycosis

Comments



N1 (1 SCORE)

- 1) Describe the lesion (0,5 point)
- 2) Make a diagnose (0,5 point)




atopic dermatitis

Font Paragraph Drawing

N2 (1 SCORE)

- 1) Describe the lesion (0,5point)
- 2) Make a diagnose (0,5 point)

Pediculosis corporis- Lice and eggs are on clothes, excoriation is covering the body. there is also papules and eruption.



Notes Comments ENG


Font Paragraph Drawing

CASE – N1 (5 score)

Patient is from south Asia, 37 years old has patches on the body, with loss of sensation of skin during last 6 months.

- 1) Primary diagnose
- 2) Differential diagnose
- 3) Lab test
- 4) Final diagnose
- 5) Treatment

leprosy (tuberculoid form)



Notes Comments ENG